

# Evaluating the Efficacy of Continuous Water-Cooling 115-Watt 6.78-MHz Monopolar RF Therapy for Fine Wrinkle Reduction

JongSeo Kim, MD

**Background:** Cosmetic procedures using radiofrequency (RF) technology have garnered significant attention as noninvasive approaches to skin rejuvenation and wrinkle reduction. This study investigates the efficacy of RF therapy in enhancing skin texture, firmness, and appearance. By harnessing the 6.78-MHz “VolNewMer” RF device, skin aging concerns, particularly in terms of skin roughness, laxity, and wrinkles, can be treated.

**Methods:** This study engaged a cohort of 50 participants seeking wrinkle reduction and skin-lifting treatments. Employing noninvasive methods, the efficacy of RF therapy was evaluated immediately posttreatment and 1-month posttreatment. Skin roughness was quantified using a computer-based analysis of standardized 3D scanner images, capturing uniform lighting and angles to ensure accurate measurements.

**Results:** Among the 45 participants who completed the study, significant improvements in skin roughness were observed. The average roughness (Ra) value decreased from 16.71 to 11.88 arbitrary units immediately posttreatment, signifying a 28.42% enhancement. At the 1-month follow-up, the Ra value further decreased to 12.33 arbitrary units, reflecting a sustained 26.23% improvement. However, 16 participants exhibited even greater improvements at 1 month than immediate.

**Conclusions:** RF therapy’s profound impact on skin tightening and rejuvenation is rooted in its ability to trigger immediate collagen contraction, bolstering skin elasticity. The dual-phase process of immediate and delayed skin improvement underscores the intricate interplay between thermal stimulation and collagen remodeling. Optimal energy levels and controlled endpoint monitoring ensure safe and effective RF treatments. The use of the VolNewMer device tips and sliding technique contributes to patient comfort and treatment precision. (*Plast Reconstr Surg Glob Open* 2024; 12:e5623; doi: [10.1097/GOX.00000000000005623](https://doi.org/10.1097/GOX.00000000000005623); Published online 26 February 2024.)

## INTRODUCTION

In recent years, the field of cosmetic dermatology has witnessed a surge in demand for noninvasive procedures that deliver remarkable aesthetic results with minimal downtime and discomfort.<sup>1</sup> Among these, radiofrequency (RF) technology has emerged as a transformative modality, offering a safe and effective means of skin rejuvenation.<sup>2</sup> This article explores the innovative RF energy-based medical devices (EBDs) and its application in noninvasive

cosmetic procedures. By delving into the underlying mechanisms, methodology, results, and implications, we aim to provide a comprehensive understanding of the potential of RF-based treatments in reshaping the landscape of cosmetic dermatology.

## METHODS

The research was conducted on a cohort of 50 individuals who visited the author’s clinic and had not undergone cosmetic procedures such as EBD, filler, and botulinum toxin treatment in the past 6 months. Participants’ age was 35- to 88-years-old.

From the Kim-Jongseo Plastic Surgery Clinic, Seoul, Korea.

Received for publication August 29, 2023; accepted November 14, 2023.

Copyright © 2024 The Author. Published by Wolters Kluwer Health, Inc. on behalf of The American Society of Plastic Surgeons. This is an open-access article distributed under the terms of the [Creative Commons Attribution-Non Commercial-No Derivatives License 4.0 \(CCBY-NC-ND\)](https://creativecommons.org/licenses/by-nc-nd/4.0/), where it is permissible to download and share the work provided it is properly cited. The work cannot be changed in any way or used commercially without permission from the journal. DOI: [10.1097/GOX.00000000000005623](https://doi.org/10.1097/GOX.00000000000005623)

Disclosure statements are at the end of this article, following the correspondence information.

Related Digital Media are available in the full-text version of the article on [www.PRSGlobalOpen.com](https://www.PRSGlobalOpen.com).

For each patient, the author administered 200–300 shots using V (4 cm<sup>2</sup>) tips of “VolNewMer” (VNM; Classys, Seoul, Korea) RF device. The intensity of the RF energy from the high-frequency equipment was set to a maximum level of 5 (115 J, 28.75 J/cm<sup>2</sup>). It is worth noting that reducing the energy level may necessitate an increase in the number of shots. Typically, patients initially receive treatment at level 5, and if the patient experiences discomfort due to the heat, the intensity is lowered to level 4 (95 J, 23.75 J/cm<sup>2</sup>) and then to level 3 (75 J, 18.75 J/cm<sup>2</sup>). VNM adopts a continuous stable water-cooling system in which epidermal temperature is maintained appropriately by contacting the tip end, where chilled water circulates, with the skin surface to control the temperature. VNM can irradiate a single 1000-ms RF pulse at a time, whereas the other RF system with gas-cooling system can irradiate multiple times 200-ms RF pulses segmentally, and this can result in more pain.

The author consistently tried to use level 5 as much as possible. To alleviate the sensation of heat discomfort, the author used a “sliding technique” when the patient reacted to the heat. The sliding technique reduces the number of shots required and diminishes the perception of intense heat. Initially, a static technique was used without moving the tip, but if the patient felt too hot, the tip was moved approximately 1 cm. If further discomfort (too hot) appeared, a sliding technique of 2 or 3 cm was adopted.

To assess the efficacy of RF-EBD in improving fine wrinkles on the face and providing skin lifting, a three-dimensional (3D) scanner was used. The skin changes were measured immediately after the procedure and 1 month later. Skin changes were quantified using a 3D scanner image (3D LifeViz mini; QuantifiCare, Sophia Antipolis, France) using computer analysis (Gwyddion data analysis software; Czech Metrology Institute, Jihlava, Czechia) for measuring skin roughness.<sup>3</sup> The 3D scanner captures standardized photographs under consistent lighting, distance, and angles (Figs. 1 and 2). This methodological approach ensured reliable and quantifiable data collection, contributing to the robustness of the study’s findings. The images using the 3D scanner were obtained and measured immediately and 1 month later. These images were then analyzed using an online computer program for measuring skin roughness, specifically the skin roughness average (Ra) (Fig. 1). [See Video 1 (online), which shows the roughness before the treatment using Gwyddion computer program.] [See Video 2 (online), which shows the roughness after the procedure using Gwyddion computer program.]

After taking the 3D image, 1 mL of cosmetic product (Gold stem ample; Reteenage, Seoul, South Korea) was sprayed under high pressure to penetrate the ample into the epidermis, and the treated area was covered with plastic wrap. This occlusive dressing was maintained for a few hours. The cosmetic product contains freezing-dry powder of stem cell conditioning media and 1% of hyaluronic acid.

One month after the procedure, patients visited the clinic without applying makeup or any other products to their faces. Three-dimensional photographs were then taken.

## Takeaways

**Question:** This study aims to assess the effectiveness of continuous water-cooling 115-Watt 6.78-MHz monopolar radiofrequency therapy in reducing fine wrinkles in non-invasive cosmetic dermatology.

**Findings:** The VolNewMer radiofrequency device revealed a significant immediate improvement in skin roughness (28.42%) after the procedure, with sustained enhancement (26.23%) observed at 1 month. The study suggests that the treatment’s effectiveness may be influenced by initial wrinkle severity and the age of participants.

**Meaning:** Notably, the findings indicate that younger individuals tend to experience further improvement in skin texture 1 month after the radiofrequency procedure, suggesting a more active collagen regeneration process in the younger age group over time.

The Global Aesthetic Improvement Scale was used for a comprehensive evaluation of the effects of the RF device on skin texture, smoothness, and wrinkles (very much improved: 5, much improved: 4, improved: 3, no change: 2, worse: 1).

## RESULTS

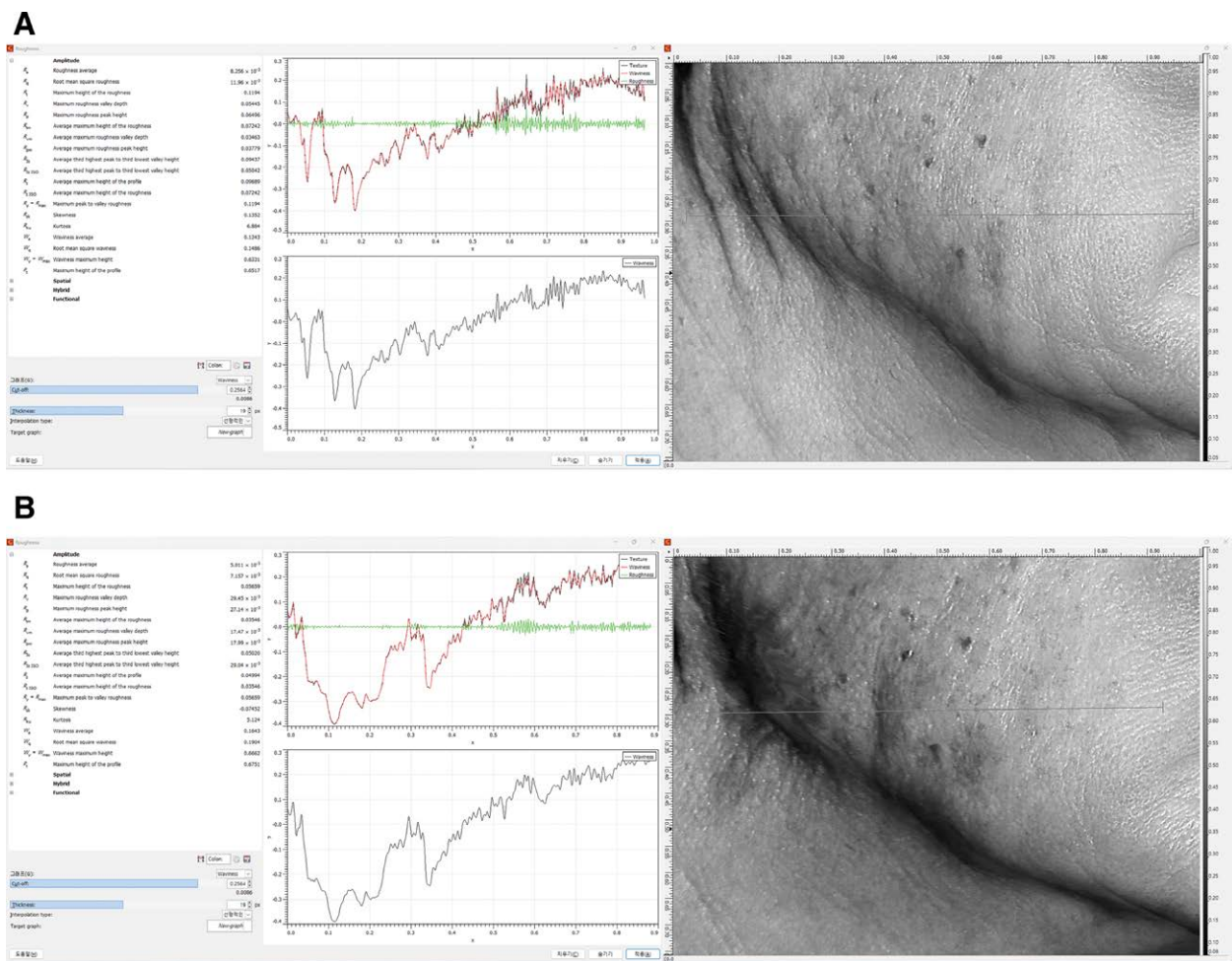
Of the initial cohort of 50 participants, five individuals did not return for their 1-month follow-up, resulting in a final sample of 45 participants who completed the study. The participants’ mean age was 45.7 years.

Before the treatment, the baseline roughness average (Ra) was measured at 16.71±6.39 arbitrary units. Immediately after the procedure, the Ra value improved to 11.88±4.77, representing a 28.42±11.64% enhancement. After 1 month, the Ra value further improved to 12.33±5.84, indicating a 26.23±8.65% improvement compared with baseline (Figs. 2–7).

Among the 45 participants who completed the 1-month follow-up, 16 individuals exhibited greater improvement in Ra values than immediate results. Most of these 16 participants had less severe wrinkles at baseline, with initial Ra values below 10 arbitrary units, or were under the age of 40. This suggests that individuals with milder initial skin conditions or younger age may experience more sustained improvement over the 1-month period through neocollagenesis (Fig. 7).

Conversely, among the 35 participants who showed better Ra values immediately posttreatment compared with 1 month later showing relapse of skin roughness, a common trend emerged. Many of these 35 individuals were 50 years of age and above, and they typically had initial Ra values exceeding 10, indicating more pronounced initial wrinkles. This pattern implies that participants with more significant wrinkles or older age might experience a relatively greater initial improvement that may gradually attenuate over the course of 1 month (Fig. 7).

The detailed analysis of the Ra values and their trends over time provides valuable insights into the varying responses



**Fig. 1.** The evaluation of skin roughness. A, Skin roughness before the RF treatment. B, Skin roughness after the RF treatment. The skin roughness has improved. This means that the skin roughness value, which represents the surface smoothness of the skin, has decreased, indicating a smoother and more even skin texture after the treatment. The RF treatment has contributed to improving the skin's fine wrinkles and roughness, resulting in a more refined and uniform skin surface.

of participants to the RF-EBD. The results suggest that the treatment's effectiveness may depend on the initial severity of wrinkles and the age of the participants. This information is essential for clinicians to personalize treatment plans and set realistic expectations for individuals seeking noninvasive wrinkle reduction and skin-lifting procedures.

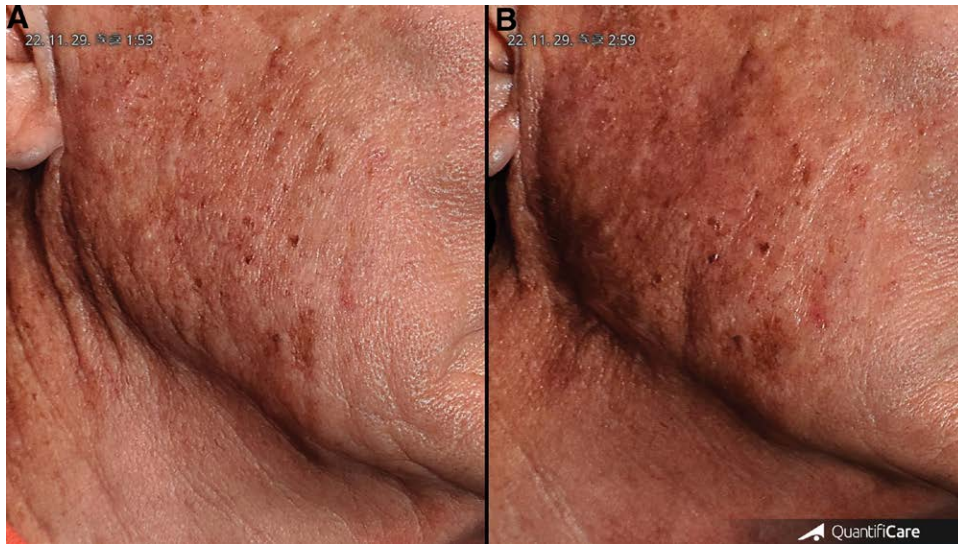Global aesthetic improvement scale score was improved after the procedure. Satisfaction with skin texture and wrinkles was higher immediately after the procedure than 1 month after, and satisfaction with skin texture gradually improved a month later (Fig. 8).

## DISCUSSION

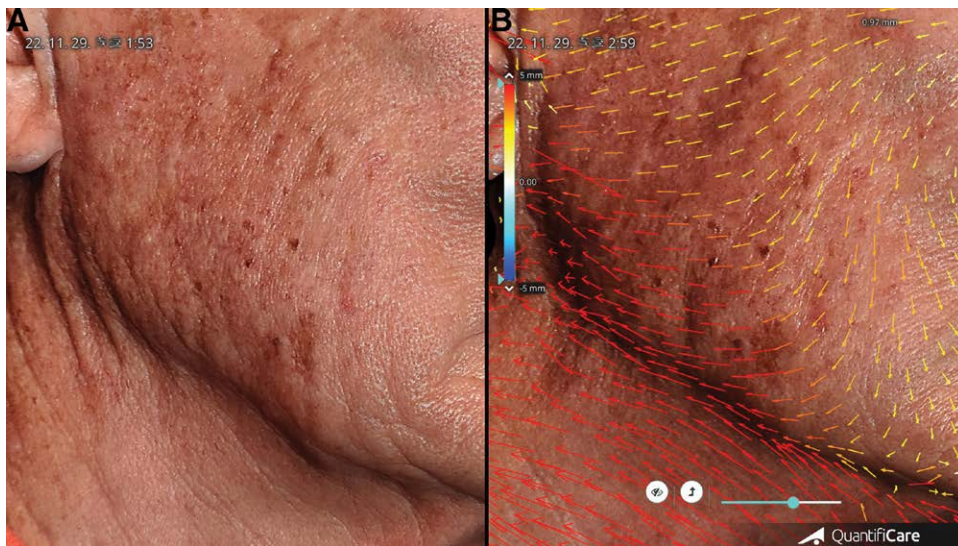
### Mechanisms of RF Therapy: Initial Contraction of Collagen and Remodeling

Following RF treatment, the skin undergoes a dual-phase response. The immediate contraction of collagen fibers in the dermis results in improvement of skin elasticity. Immediate skin contraction and tightening can be

reminiscent of the phenomenon that occurs when squid is briefly soaked in hot water and then taken out.<sup>4</sup> If you soak squid in lukewarm water when cooking, collagen shrinkage does not occur at all. This immediate contraction is a pivotal precursor for subsequent, delayed skin improvement effects. The delayed phase involves collagen remodeling due to thermal damage, characterized by fibroblast activity and the subsequent release of cytokines, the accumulation of leukocytes for wound healing, angiogenesis, and the synthesis of new collagen by fibroblasts.<sup>5</sup> RF technology orchestrates a symphony of physiological responses that culminate in profound skin rejuvenation. The initial phase of immediate collagen contraction, attributed to controlled thermal heating, results in visible tightening and enhanced skin texture. This instantaneous gratification sets the stage for the subsequent act: the delayed remodeling phase.<sup>4</sup> This second act, characterized by fibroblast activation and collagen synthesis, is where the true magic of RF therapy unfolds. Collagen, the architectural framework of the skin, is meticulously rearranged and renewed, ushering in sustained improvements



**Fig. 2.** Improvement of wrinkles and fine lines on the 3D scanner images for an 88-year-old man. A, Before the treatment. The visible wrinkles and fine lines were observed. B, Immediately after the treatment. A noticeable improvement is evident, showcasing the effective reduction of wrinkles and fine lines. Notably, the treatment yields remarkable results in specific areas, including the area below the ear and the mandibular angle area. The skin looks smoother, more youthful, and rejuvenated immediately after the procedure.



**Fig. 3.** Visual evidence in 3D analysis of effective lifting. A, Before treatment in the same patient in Figures 1 and 2. B, Immediately after the procedure. The red arrow markings indicate areas where more pronounced lifting has taken place, demonstrating the effectiveness using 3D scanner analysis.

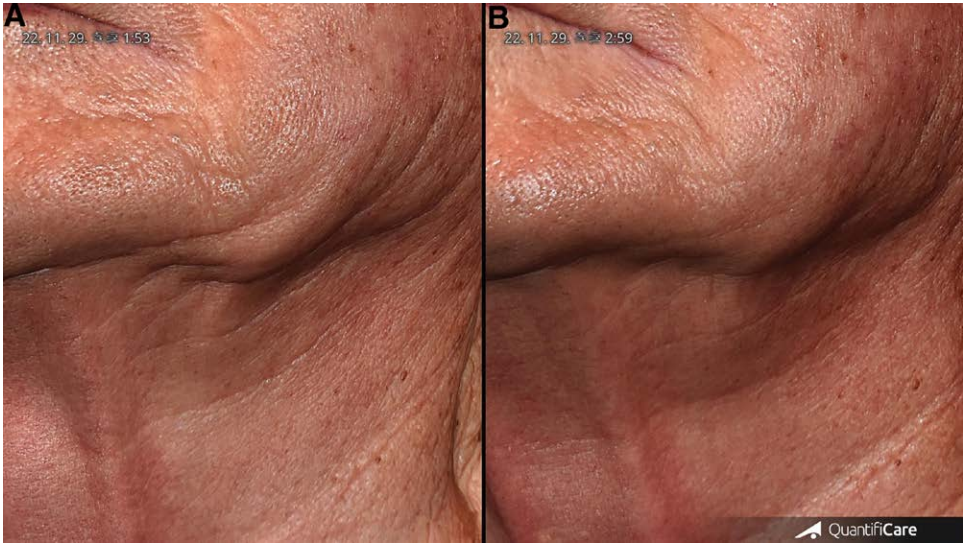
over time. As we navigate this intricate dance of biologic responses, it becomes evident that RF therapy is not a fleeting affair but an enduring commitment to skin health.

The timing and degree of these reactions depend on the balance between adequate energy application and avoiding excessive heat or energy. However, if you cook squid in too hot water for too long, the squid will become tough and hard. Excessive heat during RF treatment can be harmful to the skin and cause burns. When performing RF treatment, the appropriate temperature is to apply heat until the skin becomes tightened. A good target point

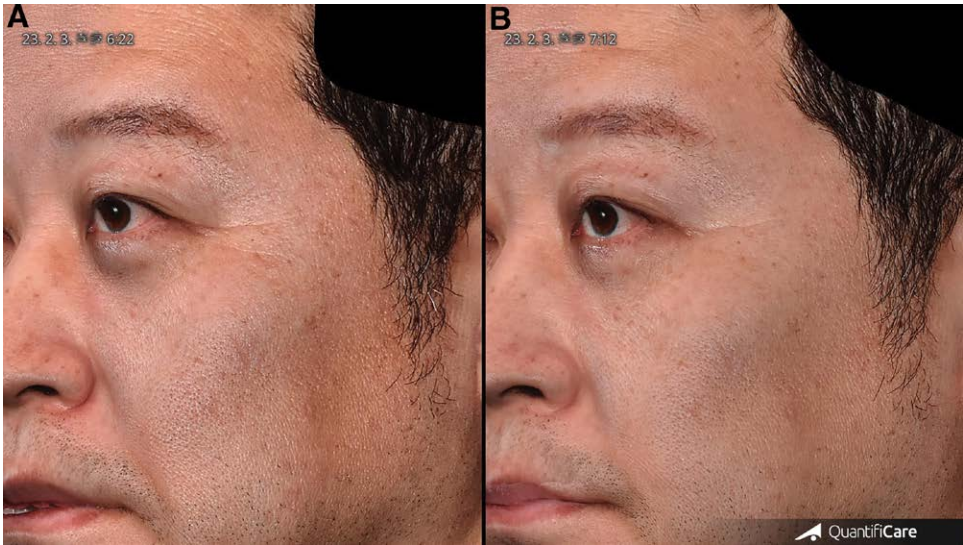
is when the patient feels tolerably hot. The author measures skin temperature using a noncontact method and uses an increase of about 8 degrees as the standard treatment of end point.

#### VolNewMer

VNM-EBD, using 115-Watt 6.78-MHz monopolar RF technology with continuous water-cooling employing 5-level water cooling, has garnered significant attention in the high-frequency therapy market in terms of price/performance similar to Thermage (TMG). VNM adopts a



**Fig. 4.** Improvement of neck fold on the 3D scanner images. A, Before treatment for the same patient in Figures 1–3. The skin and jowl fat were drooping. Prominent neck fold was found. B, Immediately post-treatment. Noticeable improvement in sagging jowls and turkey neck folds.



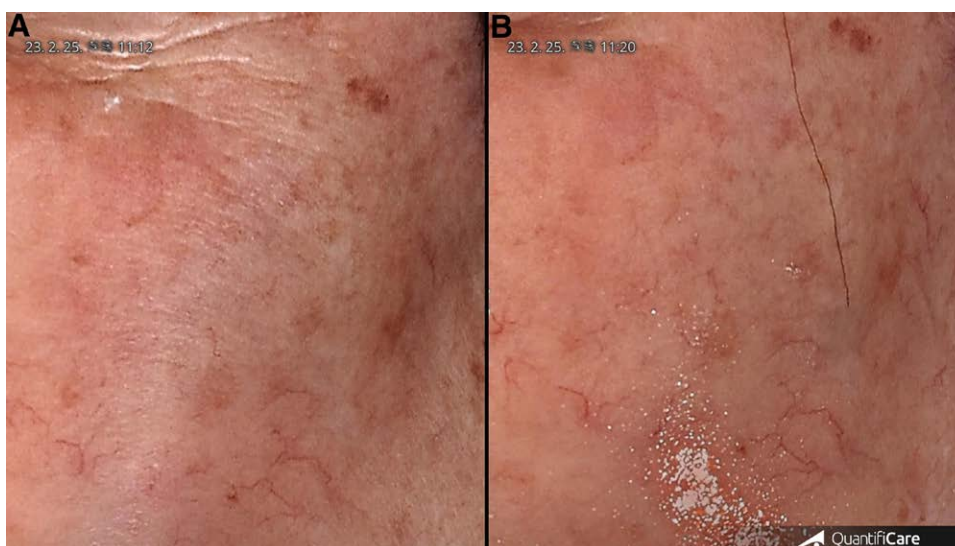
**Fig. 5.** Before and after photographs of the author's face. A, Before the procedure. B, Immediate post-self-treatment photograph by the author. Noticeable improvement in crow's feet. Overall facial fine lines show enhancement, resulting in a brighter appearance.

continuous stable water-cooling system and irradiates a single 1000-ms pulse, whereas the TMG system adopts a gas-cooling system and irradiates multiple 200-ms RF pulses segmentally, which can cause more pain than single irradiation of 1000 ms. TMG with superior cooling capabilities has the advantage of being able to transfer more energy to deep tissues; however, it may be less effective in treating fine wrinkles on the skin surface.

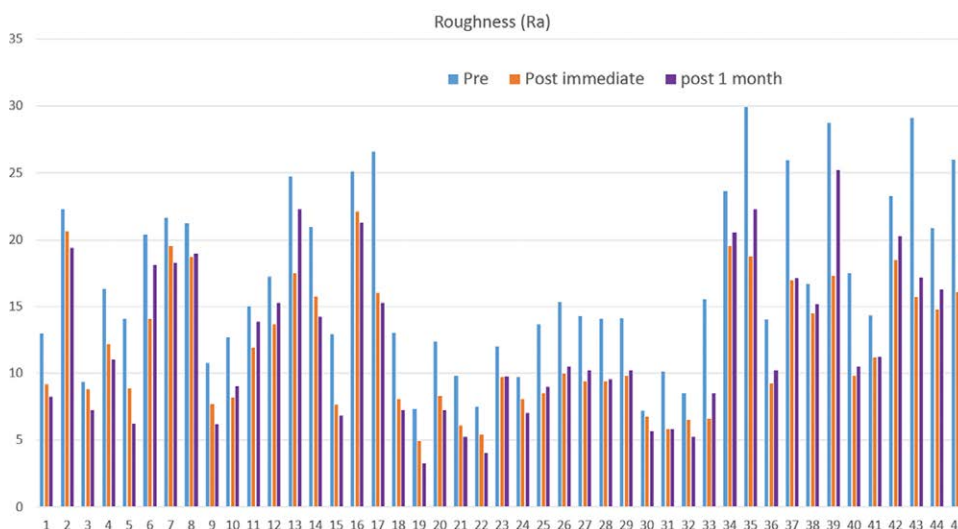
Tip options of VNM are similar to TMG. However, the unique ergonomic design of VNM tips features a curved bottom surface with an added “hidden edge” for enhanced coverage and ergonomic maneuverability. The tilting capability of the tips allows them to adapt to the facial contours,

ensuring consistent and optimal contact with the skin. The cushion function of the tips maintains constant pressure on the skin regardless of applied pressure strength.

The VNM features a sensor that alerts the user and halts energy emission when skin contact is incomplete. It is important to note that procedures interrupted in this manner are not counted as completed treatments by the device. This distinguishes VNM from other high-frequency devices such as TMG, Tentherna, or Oligio, where interrupted sessions are counted as treated instances. Its versatile tip options, cooling system, and innovative technology make it a promising tool for noninvasive skin rejuvenation procedures, offering safety, efficacy, and patient comfort.



**Fig. 6.** Three-dimensional scanner images before and after the treatment of an 83-year-old woman. A, Before the treatment. Crow's feet were sound. B, Immediate posttreatment 3D scanner image. Improvement in crow's feet. Overall facial wrinkles have improved.



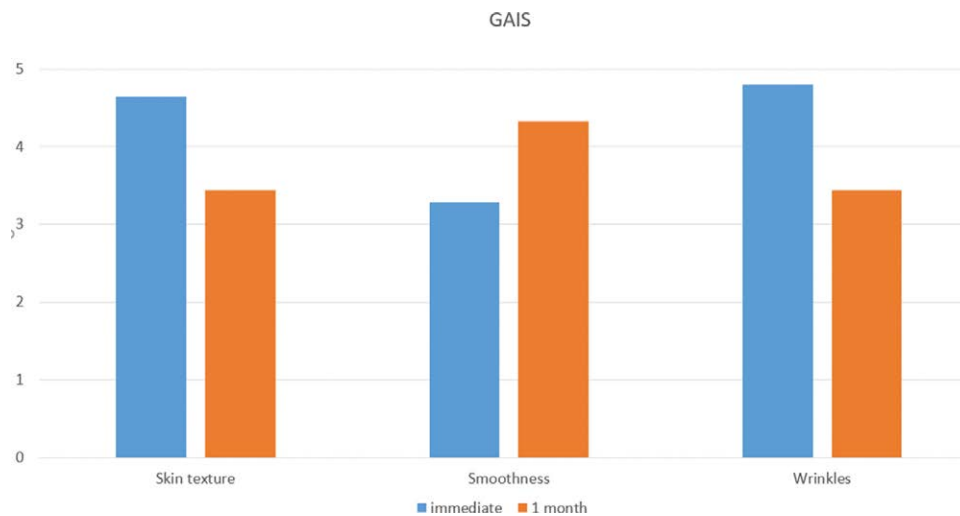
**Fig. 7.** Changes in skin roughness for 45 participants. This graph illustrates the changes in skin roughness for 45 participants. The blue color represents before the treatment, the orange color represents immediately after the treatment, and the purple color represents 1 month later.

One of the most intriguing applications of RF therapy lies in face slimming in the author's clinic, where it offers a nonsurgical avenue for facial sculpting. Research on Asian women revealed that RF therapy led to a reduction in fat accumulation in the lower face for more than 90% of participants, accompanied by high levels of satisfaction. The minimal postprocedure side effects, primarily mild redness, underscore RF therapy's safety profile.

Amid the array of benefits, the discussion candidly addresses potential risks and side effects. Temporary swelling, redness, tingling, and even pigmentation alterations can manifest post-RF therapy. However, these effects are generally transient and manageable, especially when

overseen by certified practitioners. Importantly, the article reassures readers that, despite uncertainties surrounding long-term low-energy RF effects, current evidence does not substantiate any significant health risks posed by RF energy.

Underscoring its scientific foundation, the article navigates the landscape of skin aging, unraveling the dual processes of intrinsic and extrinsic aging. The former encompasses the inexorable tissue degeneration associated with the natural aging process, whereas the latter, exemplified by photograph-damaged skin, reflects the toll of chronic UV radiation exposure. With its collagen-inducing and remodeling effects, RF therapy stands as a formidable



**Fig. 8.** The changes in GAIS for skin texture, smoothness, and wrinkles. This graph depicts the average GAIS scores for a group of 45 participants. The blue color represents immediately after the treatment, whereas the orange color represents the GAIS scores 1 month after the treatment. Although skin texture and wrinkles exhibited higher satisfaction immediately after the procedure, smoothness showed higher satisfaction 1 month later. This suggests a potential correlation with collagen regeneration, indicating the ongoing effects of the treatment over time. GAIS, global aesthetic improvement scale.

contender in offsetting these age-related skin challenges, offering tangible solutions to sagging skin and wrinkles.<sup>6</sup>

Intriguingly, the discussion delves into the realm of histological and immunostaining techniques, which provide an objective lens through which to evaluate the effects of monopolar RF therapy.<sup>7</sup> By scrutinizing collagen content, presentation, and formation, researchers gleaned valuable insights into the therapy's intricate interplay with skin tightening and appearance. The comprehensive approach encompassing multiple facets of collagen biology reinforces the robustness of RF therapy's impact on skin health.<sup>8</sup>

The discussion culminates with a resounding endorsement of RF therapy as a potent and secure modality for skin tightening and rejuvenation. By activating collagen synthesis, promoting tissue remodeling, and enhancing overall skin aesthetics, RF therapy occupies a pivotal niche in the arsenal of noninvasive cosmetic procedures. The discussion champions the use of RF therapy as a pivotal resource for individuals seeking to rejuvenate their skin's firmness, alleviate wrinkles, and embrace a more youthful and revitalized appearance.

#### Synergy with Ancillary Treatments: Elevating Rejuvenation to New Heights

In the pursuit of excellence, the integration of ancillary treatments harmonizes with RF therapy to amplify outcomes. Platelet-rich plasma (PRP) infuses growth factors, serving as a catalyst for cellular regeneration and accelerating tissue repair.<sup>9</sup> Within PRP, the concentrations of growth factors are notably elevated, ranging approximately 3–5 times higher than those found in regular plasma. This augmentation of growth factors significantly contributes to tissue healing processes. Among the plethora of growth factors encapsulated within PRP are platelet-derived endothelial growth factor, platelet-derived growth

factor A + B, transforming growth factor  $\beta$ , insulin-like growth factor 1 and 2, vascular endothelial growth factor, ECGF, and basic fibroblast growth factor, predominantly housed within the  $\alpha$  granules of platelets.<sup>9,10</sup> This rich reservoir of growth factors plays a pivotal role in initiating and orchestrating the intricate cascade of cellular events necessary for tissue regeneration and repair. This synergistic collaboration reinforces the body's natural healing mechanisms, propelling the rejuvenation process forward. Weekly PRP injections can increase rejuvenation delayed effects after RF treatment.<sup>11</sup>

Polydeoxyribonucleotide (PDRN) and polynucleotide have gained significant attention for their potential in skin antiaging therapy.<sup>12</sup> PDRN, composed of DNA fragments extracted from salmon trout or chum salmon sperm cells, has demonstrated various therapeutic properties in both preclinical and clinical studies. These properties include anti-inflammatory, antiapoptotic, antiosteoporotic, anti-melanogenetic, antiallodynic, antiosteonecrotic, bone regenerative, tissue damage preventive, antiulcerative, and wound healing effects, which are mediated through the activation of the adenosine A2A receptor and salvage pathways.<sup>12,13</sup> PDRN also promotes angiogenesis, cellular activity, collagen synthesis, soft-tissue regeneration, and skin revitalization and can even be used to treat hyperpigmentation. PDRN enters the scene as a key player, engaging adenosine A2A receptors and orchestrating a chorus of collagen synthesis and tissue reconstruction. Another crucial aspect is PDRN's ability to enhance angiogenesis, crucial for tissue repair. PDRN's promotion of vascular endothelial growth factor expression through A2A receptor activation leads to improved blood vessel formation and tissue regeneration. Furthermore, PDRN inhibits melanin synthesis, making it a potential treatment for hyperpigmentation disorders. It suppresses melanogenic

gene expression and inhibits tyrosinase enzymatic activity, contributing to skin whitening.<sup>12,13</sup> Weekly PD or PDRN injections can increase delayed rejuvenation effects.

Stem cell conditioning media (SCM) is a powerful conductor that creates an environment conducive to cellular revitalization.<sup>14</sup> SCM has emerged as a novel therapeutic approach in regenerative medicine, showing successful outcomes in certain diseases.<sup>15</sup> The emergence of SCM suggests the potential use of SCM as a new and promising alternative for skin wound healing. Despite numerous preclinical data demonstrating the potential and efficacy of this treatment, the injection of SCM is not feasible. An approach involving the use of small particles extracted for injection of SCM, known as exosomes, exists. Exosomes refer to small vesicles (30–120nm) with a double lipid membrane structure secreted by cells. However, with the discovery of various forms of vesicles secreted by cells, the term “exosome” has been extended to encompass a broader category of extracellular vesicles.<sup>16</sup> Exosomes were first discovered in 1983 and were initially perceived as a cellular “garbage bag” without clear biologic functions.<sup>17</sup> However, exosomes contain diverse ligands, cell-derived proteins, growth factors, nucleic acids, etc., and have been found to play a significant role in intercellular communication.<sup>18</sup> They carry various biologic information released by cells, contributing to disease diagnosis, new biomarker discovery research, therapeutic development using effective substances for cell signaling, and the development of drug delivery systems using the bilayer membrane structure for drug detection. Exosomes released in cell culture media, which were previously discarded, have sparked interest among researchers studying cells. According to data from the US National Library of Medicine’s PubMed database, the number of published articles has exponentially increased since 2010, with more than 46,000 articles published from 2010 to 2022, including 8721 published in the past year alone. As the growing number of publications suggests, many scientists are enthusiastic about exosomes. Exosomes maintain the functional role of traditional cell therapies while overcoming safety issues associated with cell therapies, such as immune rejection, cancer induction, and vascular occlusion, due to their nonliving nature. As a result, exosomes are recognized as a novel concept of cell-free therapeutics, advantageous for storage, transportation, and management. Immune cell-derived exosomes are being developed as targeted anticancer agents or immunotherapies, and stem cell-derived exosomes are being explored for rare and refractory disease treatments. However, because exosomes are extracted from SCM, their quantity may not surpass the effects of SCM. The extraction and concentration of exosomes present challenges for validation by the general consumers. Together, these adjunctive treatments weave an intricate tapestry of rejuvenation, heralding a holistic approach to skin health.

#### Limitations and Future Directions: Paving the Road to Advancement

Although the RF-EBD showcases remarkable potential, it is vital to acknowledge the limitations inherent to any study and treatment modality. The cohort size, albeit

robust, offers a snapshot rather than an exhaustive panorama of the diverse patient population. Further exploration with larger and more diverse cohorts is warranted to validate and extend the findings.

## CONCLUSIONS

This study proved that fine wrinkles were improved with VNM RF equipment. Measuring skin roughness or fine wrinkles requires a standardized instrumentation method. It is significant that skin roughness was objectively measured numerically using a computer program using a standardized 3D scanner.

RF-based cosmetic procedures, particularly those involving the VNM-EBD, represent a significant advancement in the realm of noninvasive skin rejuvenation. The dual-phase mechanism of immediate collagen contraction and delayed remodeling underscores the transformative potential of RF therapy. The integration of ancillary treatments further amplifies the holistic approach to skin health, offering patients comprehensive solutions for their aesthetic concerns.

As the field of cosmetic dermatology continues to evolve, RF-based procedures are poised to play an increasingly prominent role in delivering effective and personalized treatments. The synergy between RF therapy and emerging technologies, coupled with a deeper understanding of biologic responses, promises to reshape the landscape of aesthetic enhancements. With RF-based procedures, individuals can embark on a journey to revitalized and youthful skin, embracing the possibilities of noninvasive treatments while minimizing risks and downtime.

The VNM RF-EBD exemplifies the convergence of innovation, science, and artistry in modern cosmetic dermatology. With its transformative potential, this technology stands as a beacon of hope for individuals seeking effective, safe, and minimally invasive solutions for their aesthetic aspirations.

**JongSeo Kim, MD**

Kim-Jongseo Plastic Surgery Clinic  
842, Nonhyeon-ro  
Gangnam-gu, Seoul, Korea  
E-mail: [plastic@surgery.co.kr](mailto:plastic@surgery.co.kr)  
Instagram: @reteenage

## DISCLOSURE

*The author has no financial interest to declare in relation to the content of this article.*

## PATIENT CONSENT

*Patients provided written consent for the use of their images.*

## ACKNOWLEDGMENT

*The author expresses thanks to Young-Ji Ahn, medical writer.*

## REFERENCES

1. Nelson AA, Beynet D, Lask GP. A novel non-invasive radiofrequency dermal heating device for skin tightening of the face and neck. *J Cosmet Laser Ther*. 2015;17:307–312.

2. Austin, GK, Struble, SL, Quatela, VC. Evaluating the effectiveness and safety of radiofrequency for face and neck rejuvenation: a systematic review. *Lasers Surg Med.* 2022;54:27–45.
3. Richard G, Yael H. Novel approach to facial rejuvenation by treating cutaneous and soft tissue for wrinkles reduction: first experience from multicenter clinical trial. *Facial Plast Surg Aesthet Med.* 2023;26:1–6.
4. Zelickson BD, Kist D, Bernstein E, et al. Histological and ultra-structural evaluation of the effects of a radiofrequency-based nonablative dermal remodeling device: a pilot study. *Arch Dermatol.* 2004;140:204–209.
5. Wang J, Dodd C, Shankowsky HA, et al. Deep dermal fibroblasts contribute to hypertrophic scarring. *Lab Invest.* 2008;88:p1278–p1290.
6. Lucas RM, Yazar S, Young AR, et al. Human health in relation to exposure to solar ultraviolet radiation under changing stratospheric ozone and climate. *Photochem Photobiol Sci.* 2019;18:641–680.
7. Sun HS, Yoon HL, Nark-Kyoung R, et al. Skin aging from mechanisms to interventions: focusing on dermal aging. *Front Physiol.* 2023;14:1195272.
8. Basak Y-A, Gonca E. Dermatology and restorative medicine. In: Vargel İ, Özgür FF (eds.), *Beauty, Aging, and AntiAging.* 2023:289–302.
9. Joseph G, Robert B. The effects of autologous platelet rich plasma and various growth factors on non-transplanted miniaturized hair. *Hair Transpl Forum Int.* 2009;19:49–50.
10. Gonshor A. Technique for producing platelet-rich plasma and platelet concentrate: background and process. *Intern J Periodontics Restorative Dent.* 2002;22:546–556.
11. Chung SW, Song BW, Kim YH, et al. Effect of platelet-rich plasma and porcine dermal collagen graft augmentation for rotator cuff healing in a rabbit model. *Am J Sports Med.* 2013;41:2909–2918.
12. Aawrish K, Guobao W, Feng Z, et al. Polydeoxyribonucleotide: a promising skin anti-aging agent. *Chinese J Plast Reconstr Surg.* 2022;14:187–193.
13. Hwang JT, Lee SS, Han SH, et al. Correction to: polydeoxyribonucleotide and polynucleotide improve tendon healing and decrease fatty degeneration in a rat cuff repair model. *Tissue Eng Regen Med.* 2023;20:789–791.
14. Sambhi M, Chow T, Whiteley J, et al. Acellular mouse kidney ECM can be used as a three-dimensional substrate to test the differentiation potential of embryonic stem cell derived renal progenitors. *Stem Cell Rev Rep.* 2017;13:513–531.
15. Chen KG, Mallon BS, McKay RD, et al. Human pluripotent stem cell culture: considerations for maintenance, expansion, and therapeutics. *Cell Stem Cell.* 2014;14:13–26.
16. Kalluri R, LeBleu VS. The biology, function, and biomedical applications of exosomes. *Science.* 2020;367:eaau6977.
17. Raghu K. The biology and function of exosomes in cancer. *J Clin Invest.* 2016;126:1208–1215.
18. Hannafon BN, Ding W-Q. Intercellular communication by exosome-derived microRNAs in cancer. *Int J Mol Sci.* 2013;14:14240–14269.