

Multi-Center, Double-Blind, Vehicle-Controlled Clinical Trial of an Alpha and Beta Defensin-Containing Anti-Aging Skin Care Regimen With Clinical, Histopathologic, Immunohistochemical, Photographic, and Ultrasound Evaluation

Amy Taub MD,^a Vivian Bucay MD,^b Gregory Keller MD,^c Jay Williams PhD,^c and Darius Mehregan MD^d

^aAdvanced Dermatology/Skinfo, Lincolnshire, IL; Northwestern University Medical School, Department of Dermatology, Chicago, IL

^bBucay Center for Dermatology and Aesthetics, San Antonio, TX

^cGregory Keller Plastic Surgery, Santa Barbara, CA

^dWayne State University, Monroe, MI

ABSTRACT

Background/Objectives: Anti-aging strategies utilizing stem cells are in the forefront. Alpha and beta defensins are natural immune peptides that have been shown to activate an LGR6-positive stem cell locus in the hair follicle, identified as the source of most new epidermal cells during acute wound healing. We investigated the ability of biomimetic alpha and beta defensin molecules, supplemented with supportive cosmetic ingredients, formulated into three skin care products, at improving the structure and function of aging skin.

Methods: A participant- and investigator -blinded, placebo-controlled, multi-center trial was performed in outpatient settings. Forty-four healthy female subjects, aged 41-71 years, skin types I-V, completed the study with 2/3 receiving full formula and 1/3 receiving the placebo formula. A skin care regimen of 3 products (serum, cream, and mask) containing alpha-defensin 5 and beta-defensin 3, and other cosmetic ingredients, was applied to the face, post-auricular, and neck skin two times per day for 12 weeks in those receiving full formula, whereas the placebo group received the identically packaged regimen without the active ingredients. Methods of evaluation included histopathology and immunohistochemistry (7 subjects), clinical evaluation of pores, superficial and deep wrinkles based on Griffiths scale, and high-resolution photography (all subjects). In addition, a subset of 15 patients were evaluated with the QuantifiCare system (3-dimensional imaging and skin care scores for evenness, pores, oiliness) and Cortex measurements (high-resolution skin ultrasound, TEWL, elasticity, color, and hydration). Data points for evaluation included baseline, 6 weeks, and 12 weeks. All patients used the same sunscreen and cleanser, which was provided to them.

Results: The full formula regimen caused a significantly ($P=0.027$) increased thickness of the epidermis as seen in histology, not seen in the placebo group, with no signs of inflammation. No excessive cell proliferation was detected in either group as measured by Ki67-immunohistochemistry. Reduction in visible pores, superficial wrinkles, oiliness, pigmentation, and improvement of skin evenness, were statistically significant. A trend for improvement was also observed in skin elasticity, TEWL, and hydration; these did not achieve statistical significance. Ultrasound and histopathology demonstrated increases in dermal thickness in individual patients, without statistical significance. Comprehensive improvement in all 5 parameters, including visible pores, hyperpigmentation, superficial and deep wrinkles, and epidermal thickness, was statistically significant when the subset of participants assigned for histology in full formula group was compared with the placebo group participants.

Conclusions: A 3-product skin care regimen containing alpha and beta defensins globally improves the visual appearance and structure of aging skin without irritation, dryness, or inflammation. Specifically, this regimen increases epidermal thickness, reduces appearance of pores, reduces wrinkles, and reduces melanin. This skin care regimen stimulates rejuvenation without evidence of increase of a marker of carcinogenic stimulation. This data is consistent with the hypothesis that a defensin-containing skin care regimen activates the body's own dormant stem cells to generate healthy new epidermal cells.

J Drugs Dermatol. 2018;17(4):426-441.

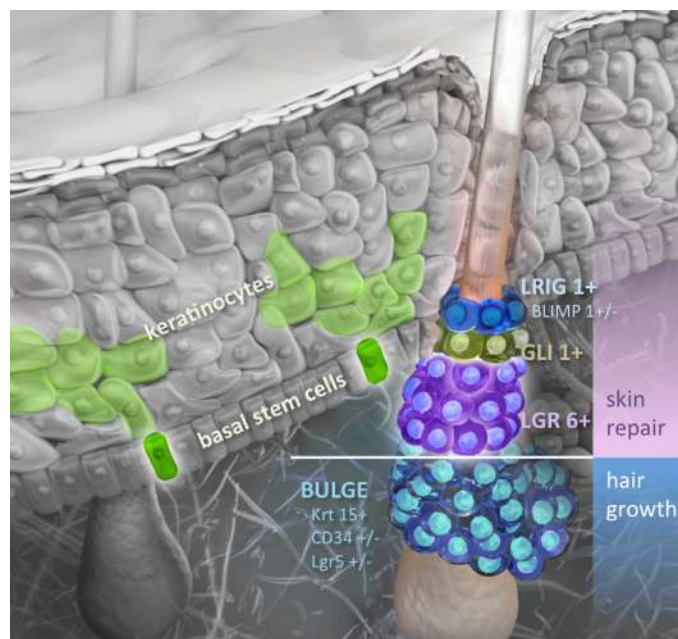
INTRODUCTION

The human epidermis consists of layers of keratinocytes at various levels of differentiation, ranging from the mitotically active basal layer to the dead flattened cells of the stratum corneum.^{1,2} Epidermal appendages include the hair follicles, sebaceous glands, and sweat glands, which extend into the dermis.³ The epidermis is maintained and regenerated by basal layer stem cells.²

Multipotent stem cells have paved the way for new applications and deeper understanding in the field of regenerative medicine and the pathophysiology of aging.^{4,5}

Various studies have characterized dermatological stem cell populations and their coordination with one another (Figure 1).^{1-3,6-10} Basal epidermal stem cells proliferate and maintain

FIGURE 1. Dermatologic stem cells. Basal stem cells support epidermal turnover and keratinocyte renewal.⁶⁻¹⁰ Bulge stem cells in hair follicle (WNT-dependent cells) are primarily responsible for hair growth due their ability to respond to WNT, the major hair growth signal. Stem cells located above bulge of hair follicle (WNT-independent cells) enable epidermis repair in wounds and support other than hair growth skin's functions; these cells cannot contribute to hair growth because they have no WNT receptors and therefore are unable to respond to hair-growth signal.

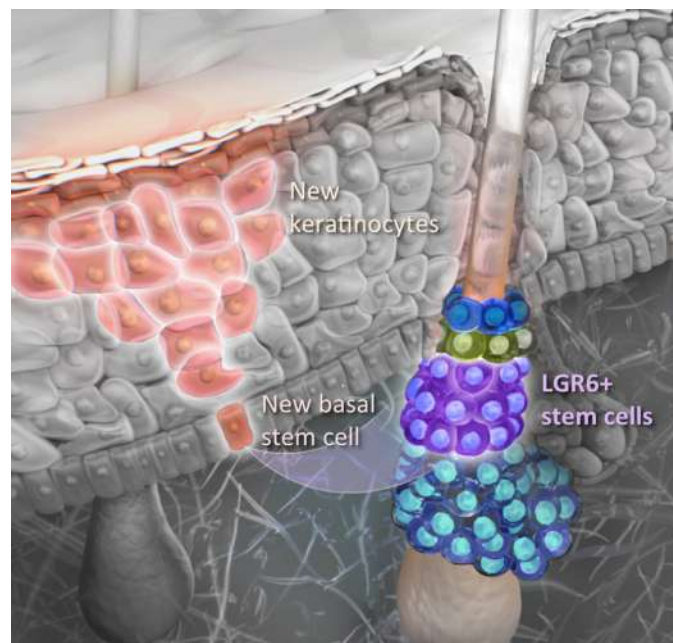


epidermal turnover and homeostasis.¹⁻³ LRIG1-positive and GLI1-positive stem cells contribute to the maintenance of the infundibulum and sebaceous glands, respectively.⁶ Hair follicle bulge stem cells are responsible for hair growth but not homeostasis of the epidermis.⁷ Located right above the hair follicle bulge, LGR6-positive stem cells create the entire epidermis and appendages early in utero,⁸ thus earning the designation "skin's master stem cells".^{6,8,9} These cells do not contribute to the skin's homeostasis on a daily basis, remaining dormant until activated by the healing cascade unleashed by a skin wound.¹⁰

During wounding, LGR6-positive cells create new keratinocytes and new epidermal basal stem cells that provide long-lasting contributions to the skin post-wounding.^{6,9,10} Activation of these cells during wounding is mediated by defensin peptides, which normally function as part of the epithelium's immune response (Figure 2).¹⁰

The human body expresses two types of defensins: alpha and beta defensins.¹¹ In addition to activation of LGR6-positive stem cells,¹⁰ defensins have a variety of potentially useful properties. They are cytotoxic to tumor cells^{12,13}; activate immature dendritic cells¹⁴; stimulate lung fibroblast proliferation and collagen

FIGURE 2. Activated by defensin peptides, dormant LGR6-positive stem cells create new basal stem cells and thus stimulate the creation of new keratinocytes.




synthesis¹⁵; function in adaptive immunity, fertility, and wound healing,¹⁶ and improve the function of the epithelial tight-junction barrier in human keratinocytes.¹⁷

In the last decade, products containing growth factors created from the supernatant or the cytoplasm of human skin cells have taken the front row in the theater of anti-aging skin care.¹⁸ Defensins are a group of peptides that are functionally and structurally different from growth factors (Figure 3).¹¹

The use of defensins to specifically activate LGR6-positive stem cells represents a novel approach to the treatment of aging skin. Unlike prior skin care ingredients and treatments (including growth factors) that activate and stimulate aged

FIGURE 3. Defensins are not growth factors. Defensins are a group of antimicrobial peptides that are functionally and structurally different from growth factors.



cells of the skin,¹⁹ defensins mobilize normally quiescent and relatively undamaged stem cells.²⁰ The targeted and specific use of defensins to activate LGR6-positive stem cells may provide a safer and more effective and targeted approach to skin aging therapy. A six-week pilot study in which 22 human subjects applied a skin care regimen of synthetic α -defensin 5 and β -defensin 3 was reported in 2014 (Keller). The results showed a global improvement in wrinkles, pores, skin's evenness, and a reduction in skin oil production. These encouraging results led to the present study, which evaluates an anti-aging skin care product containing alpha and beta defensins in 44 patients over 12 weeks.

METHODS

Study Design Overview

Institutional Review Board approval was obtained for this study and the study was performed using Good Clinical Practice Guidelines²¹ as published by the U.S. Food and Drug Administration (FDA). This is an investigator-initiated study that was registered at clinicaltrials.gov prior to subject enrollment (#NCT02765763). All study participants who met inclusion criteria and were enrolled into the study were split into two groups: the study subjects of the full formula group (FFG) used treatment contained all active substances, a three-product group consisting of a serum, a cream, and a mask. The study subjects of the placebo group (PG) used only vehicle formulas (no active ingredients) in containers and a serum, cream, and mask that were otherwise identical to the FFG. Both the study subjects and their physicians were blinded in terms of the treatment groups (double-blinded study). The participants were assigned to groups by the research coordinator in a random fashion and without the investigator's or participant's knowledge (a randomized study). Subjects were evaluated at baseline, 6 weeks, and 12 weeks.

Population

Forty-six female subjects participated in this study (15-16 participants per clinical site). Inclusion criteria included female gender, ages 40-75, any skin type, and anyone in good health who can freely participate voluntarily and agreed to potentially have a biopsy in the post-auricular area before and at either 6 weeks or 12 weeks after usage of the study materials. Exclusion criteria included current use of topical or systemic anti-aging therapy, a history of any acute or chronic disease that might interfere with or increase the risk of study participation, chronic skin allergies, history of skin cancer treated within the last 12 months, or insulin-dependent diabetes. Also excluded were individuals who had undergone any of the following procedures: Botulinum toxin, lasers or tissue tightening devices, or other energy based devices used on the face or neck within 6 months before enrollment into the study and until study completion, injectable filler within 3 months before enrollment into the study and until study completion, poly-L-lactic acid or bovine collagen

with polymethylmethacrylate at any time prior to enrollment into the study and until study completion.

Subjects underwent a 1-week washout period to remove all anti-aging skin care products, if any were utilized (antioxidants, retinol or retinoid, alpha hydroxy acid, peptides, growth factors).

Participants were randomly assigned to the PG (15 participants, 4-5 per clinical site) or to the FFG (31 participants, 9-11 per clinical site). Clinical sites included: (Site 1) Advanced Dermatology, Lincolnshire and Glencoe, IL, (Site 2) Bucay Center for Dermatology and Aesthetics, San Antonio, TX, and (Site 3) Gregory Keller Facial Plastic Surgery, Santa Barbara, CA. The mean age of the subjects in both the FFG and PG was 60 years. In the FFG, the age range was 41-69 years, Fitzpatrick's skin types I-V. In the PG, the age range was 45-71 years, Fitzpatrick's skin types II-IV. Forty-six participants were recruited and 44 participants completed the study. There was one dropout from the FFG at Site 2 and one dropout from PG at Site 3, (neither were product-related).

Study Procedure

A skin care regimen containing liposome-incorporated, synthetically produced biomimetic alpha-defensin 5 and beta-defensin 3, were tested in this study. The regimen (DefenAge®, Progenitor Biologics LLC, (a division of MediCell Technologies, Carlsbad, CA) included the 2-Minute Reveal Masque (mask applied once or twice weekly), 24/7 Barrier Balance Cream (cream applied BID), and 8-in-1 BioSerum (serum applied BID) either supplemented with the performance ingredients (FFG) or without the performance ingredients (vehicle only, PG). Placebo product was identical to full formula product in packaging. The lists of ingredients of full formula product and placebo products are shown in Table 1.

The test products (in both FFG and PG) were applied directly on the face, postauricular, and neck skin for 12 weeks. All study subjects also washed these testing areas of the skin twice daily with Topix Non-Drying Gentle Cleanser Lotion (Ingredients: purified water, dea-lauryl sulfate, propylene glycol, cetyl alcohol, stearyl alcohol, hydroxyethylcellulose, methylparaben, propylparaben, methylchloroisothiazolinone, methylisothiazolinone, FD&C Blue #1) and used Topix Elite Sunscreen SPF 30 (Ingredients: zinc oxide 17%, purified water, C12-15 alkyl benzoate, cyclomethicone, laurylmethicone copolyol, C13-14 isoparaffin, polyacrylamide, ceresin, dimethicone, green tea extract, phospholipids, ascorbyl palmitate, tocopheryl acetate, retinyl palmitate, Co-Q10, ascorbyl glucosamine, superoxide dismutase, laureth-7, sodium chloride, methylparaben, propylparaben, diazolidinyl urea) daily each morning after application of the testing regimen.

Study Methods

All 46 participants underwent medical imaging using the VISIA CA (Bucay), CR (Canfield, NJ; Taub), or the 3D LifeViz (QuantifiCare, France; Keller) along with evaluation of skin conditions

TABLE 1.

Ingredients of Full Formula and Placebo

Mask		Cream		Serum	
Full Formula	Placebo	Full Formula	Placebo	Full Formula	Placebo
Butylene Glycol, PEG-8, Tapioca Starch, Sucrose, Titanium Dioxide, Hydroxyethyl Acrylate/Sodium Acryloyldimethyl Taurate Copolymer, Squalane, Polysorbate 60, Carica Papaya (Papaya) Fruit, Papain, Aloe Barbadensis Leaf Juice, Lactobacillus/Pumpkin Ferment Extract, Lactobacillus/Punica Granatum Fruit Ferment Extract, Sea Whip Extract, Cananga Odorata Flower Oil, Citrus Aurantium Dulcis (Orange) Peel Oil, Caprylic/Capric Triglyceride, Lactic Acid, Phenoxyethanol, Caprylyl Glycol, Ethylhexylglycerin, Hexylene Glycol.	Butylene Glycol, PEG-8, Tapioca Starch, Titanium Dioxide, Hydroxyethyl Acrylate/Sodium Acryloyldimethyl Taurate Copolymer, Squalane, Polysorbate 60, Cananga Odorata Flower Oil, Citrus Aurantium Dulcis (Orange) Peel Oil, Caprylic/Capric Triglyceride, Lactic Acid, Phenoxyethanol, Caprylyl Glycol, Ethylhexylglycerin, Hexylene Glycol.	Water (Aqua), CarthamusTinctorius (Safflower) Oleosomes, Butyrospermum Parkii (Shea) Butter, Macadamia Integrifolia Seed Oil, Niacinamide, Yeast Extract, Ammonium Acryloyldimethyltaurate/VP Copolymer, Helianthus Annuus (Sunflower) Seed Oil, Rosmarinus Officinalis (Rosemary) Leaf Extract, Xanthan Gum, Phytic Acid, Polysorbate 20, Caprylic/Capric Triglyceride, Phenoxyethanol, Caprylyl Glycol, Ethylhexylglycerin, Hexylene Glycol, Potassium Sorbate, Sodium Chloride, Fragrance.	Water (Aqua), CarthamusTinctorius (Safflower) Oleosomes, Butyrospermum Parkii (Shea) Butter, Macadamia Integrifolia Seed Oil, Ammonium Acryloyldimethyltaurate/VP Copolymer, Helianthus Annuus (Sunflower) Seed Oil, Rosmarinus Officinalis (Rosemary) Leaf Extract, Xanthan Gum, Phytic Acid, Polysorbate 20, Caprylic/Capric Triglyceride, Phenoxyethanol, Caprylyl Glycol, Ethylhexylglycerin, Hexylene Glycol, Potassium Sorbate, Sodium Chloride, Fragrance.	Water (Aqua), Cyclopentasiloxane, Glycerin, Niacinamide, Sinorhizobium Meliloti Ferment Filtrate, Dimethicone, Polysorbate 20, Dimethicone/Vinyl Dimethicone Crosspolymer, Lauryl PEG-9 Polydimethylsiloxylethyl Dimethicone, Ammonium Acryloyldimethyltaurate/VP Copolymer, Phospholipids, Alpha-Defensin 5, Beta-Defensin 3, Palmitoyl Tripeptide-38, Sodium Hyaluronate, Arabidopsis Thaliana Extract, Sea Whip Extract, Ergothioneine, Helianthus Annuus (Sunflower) Seed Oil, Rosmarinus Officinalis (Rosemary) Leaf Extract, SH Oligopeptide-1, Tocopheryl Acetate, Ubiquinone, Leuconostoc/Radish Root Ferment Filtrate, Albumin, L-Alanyl-L-Glutamine, Caprylic/Capric Triglyceride, Cetyl Hydroxyethylcellulose, Lecithin, Hydroxypropyl Cyclodextrin, Phytic Acid, Phenoxyethanol, Caprylyl Glycol, Ethylhexylglycerin, Hexylene Glycol, Sodium Chloride.	Water (Aqua), Cyclopentasiloxane, Glycerin, Dimethicone, Polysorbate 20, Dimethicone/Vinyl Dimethicone Crosspolymer, Lauryl PEG-9 Polydimethylsiloxylethyl Dimethicone, Ammonium Acryloyldimethyltaurate/VP Copolymer, Helianthus Annuus (Sunflower) Seed Oil, Rosmarinus Officinalis (Rosemary) Leaf Extract, Caprylic/Capric Triglyceride, Phytic Acid, Phenoxyethanol, Caprylyl Glycol, Ethylhexylglycerin, Hexylene Glycol, Sodium Chloride.

based in Griffiths scale (clinical evaluation by investigators).²² A punch biopsy of post-auricular skin of 7 randomly chosen study participants (3 and 4 from PG and the FFG groups, respectively, at Sites 1 and 2). Biopsies were analyzed by H and E histopathology and immunohistochemistry analysis for Ki67 marker by a board certified dermatopathologist (Mehregan). Skin of 15 participants (Site 3) underwent non-invasive

multi-parameter skin testing using DermaLab® SkinLab Combo Suite (Cortex Technologies, Denmark). The testing included high-resolution skin ultrasound (dermis), the measurements of transepidermal water loss (TEWL), skin elasticity, skin color (melanin), and skin hydration. In addition, individual skin health scores (evenness, pores, and oiliness) for the same 15 study participants were calculated using 3-dimensional

TABLE 2.**Griffiths Scale**

Skin Attribute	Grading Scale				
	0	1	2	3	4
Pores	None visible	Mildly enlarged	Moderately enlarged, localized- large areas	Moderately enlarged, large areas	Markedly enlarged, local or large areas
Superficial Wrinkles	None visible	Mild	Moderate, localized to large areas	Moderate, large areas	Marked, local or large areas
Deep Wrinkles	None visible	Mild	Moderate, localized- large areas	Moderate, large areas	Marked, local or large areas
Hyperpigmentation	No hyperpigmentation	Light hyperpigmentation involving small areas	Moderate hyperpigmentation involving small areas; light hyperpigmentation involving moderate areas	Moderate hyperpigmentation involving moderate sized areas; light hyperpigmentation involving large areas; small areas of marked hyperpigmentation	Marked hyperpigmentation involving moderate or large sized areas
Erythema	None visible	Minimal-barely perceptible erythema	Mild-predominantly minimal erythema (pink) in the treated area with or without a few isolated areas of more intense erythema	Moderate-predominantly moderate erythema (red) in the treated areas with or without a few isolated areas of intense erythema (bright red)	Severe-predominantly intense erythema (bright red) in the treated area with or without a few isolated areas of very intense (fiery red) erythema
Scaling and Dryness	None visible	Minimal-barely perceptible desquamation	Mild-limited areas of fine desquamation in up to 1/3 of the treatment area	Moderate-fine desquamation involving 1/3 to 2/3 of the treatment area or limited areas of coarser scale	Severe-coarser scaling involving more than 2/3 of the treatment area or limited areas of very coarse scaling

image analysis of LifeViz App (QuantifiCare, France) and then compared to QuantifiCare's reference population database of normal aging skin, adjusted for age, sex, and skin type; the 3-dimensional high-resolution micro-imaging of skin surface of those participants were taken using micro imaging system (QuantifiCare, France).

Griffiths scale

We have used the original scale described by Griffiths.²² Specific skin attributes are shown in Table 2.

Statistical Methods

All statistical analysis was performed using R (Ver. 3.4.1). Significance was set a priori at $P < 0.05$.

Two-sample student's t-test was used to compare the improvement at 6 weeks and 12 weeks between the two groups (PG vs FFG) for each of the parameters for analysis of the data acquired using Cortex and QuantifiCare systems, and histopathology (epidermal thickness) and immunohistopathology (Ki67) data.

Descriptive summaries are expressed as means \pm standard deviation (SD).

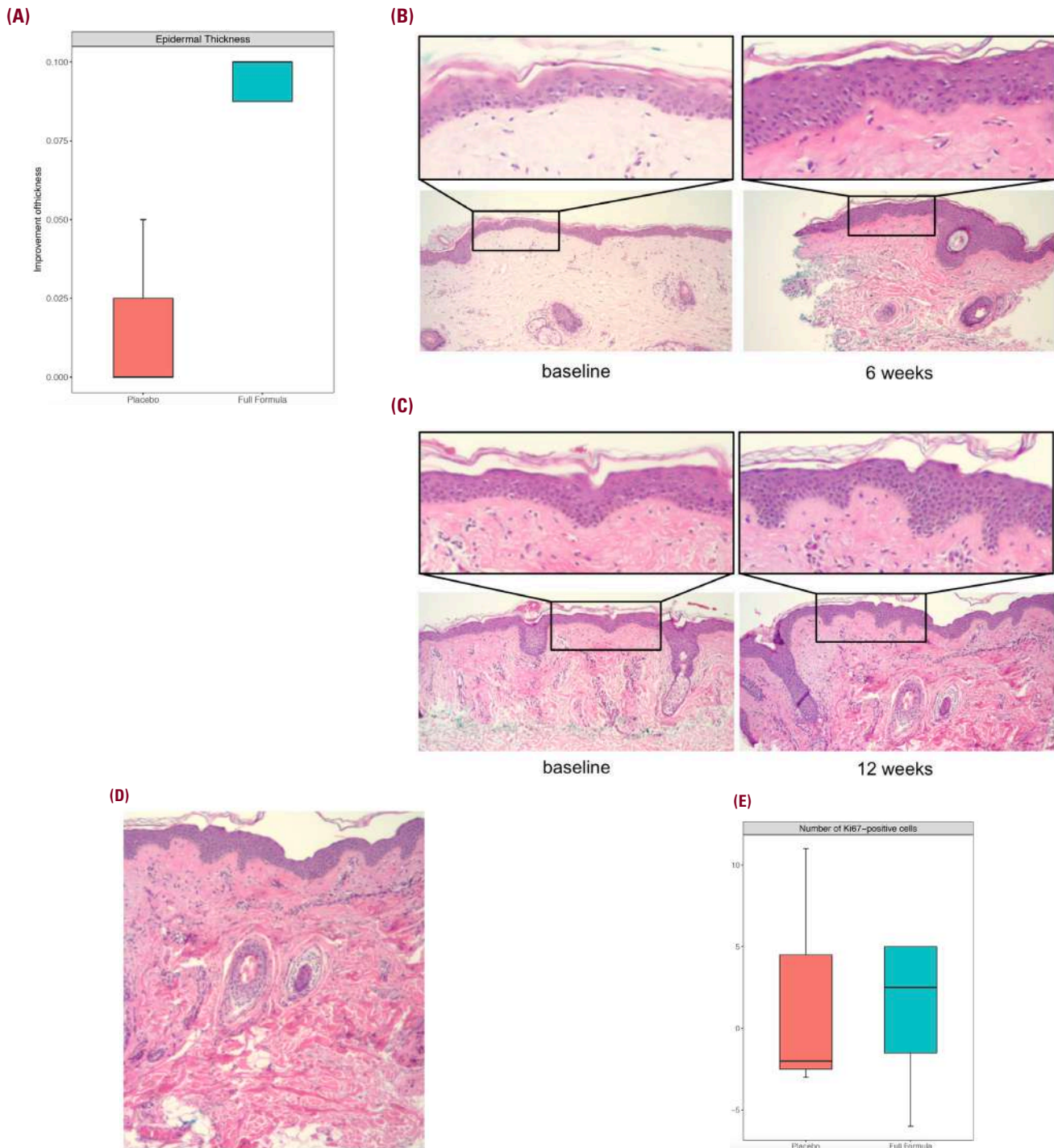
Fisher's Exact test was used to compare the improvement percentage at 6 weeks and 12 weeks between the two groups (PG vs FFG) to analyze the Griffiths scale data. Descriptive summaries are expressed as frequency and percentage.

RESULTS

The histopathological analysis revealed an increase of the epidermal thickness in all four participants of the FFG assigned for skin biopsy and less or no increase in the PG. The increase in epidermal thickness in the FFG was 0.09 ± 0.02 mm (average) vs 0.02 ± 0.03 mm in the PG ($P = 0.027$; Figure 4A, B, C).

The regimen did not appear to cause inflammation, as was seen in the histopathology analysis via lack of inflammatory cells and absence of spongiosis in FFG (also none seen in PG; Figure 4D). The microscopic lack of inflammation was

FIGURE 4. The Full Formula causes thickening of the epidermis and dermis without visible signs of inflammation or significant increase in number of proliferating cells. **(A)** Thickness of epidermis (average per group, mm) measured on histology samples collected after 6 or 12 weeks of treatment. The mean differences between baseline and after treatment are shown. **(B, C)** Hematoxylin and Eosin staining of skin biopsy samples collected from participants of the Full Formula group: participant #4 **(B)** and #10 **(C)**. The images indicate an increased number of keratinocytes in the epidermis and the thickening of the epidermis, observed in all participants of the Full Formula group assigned for histopathological evaluation. Photos were taken at 10x magnification. **(D)** Hematoxylin and Eosin staining of skin biopsy samples collected from participant #10 of the Full Formula group demonstrates the lack of signs of inflammation after 12 weeks of treatment. Photo was taken at 10x magnification. **(E)** Number of Ki-67 positive cells (average per group) counted in biopsy samples collected after 6 or 12 weeks of treatment indicates that the Full Formula and placebo formulas did not cause significant proliferation in the skin. The mean differences between baseline and treatment are shown.



© 2018-Journal of Drugs in Dermatology. All Rights Reserved.

This document contains proprietary information, images and marks of Journal of Drugs in Dermatology (JDD).

No reproduction or use of any portion of the contents of these materials may be made without the express written consent of JDD.

If you feel you have obtained this copy illegally, please contact JDD immediately at support@jddonline.com

TABLE 3.

Product Tolerance Demonstrated by Participants of Full Formula Group

	Parameter	Score (average per group)		
		Baseline	6 week	12 week
Griffiths Scale	Erythema	1.17	1.2	1.11
	Scaling and Dryness	0.63	0.43	0.39
Consumer Survey	Dry Skin	3.52	5.28	5.37
	Facial skin tightness after washing	3.69	5.1	5.11
	Facial skin is uncomfortable during day	5.17	5.53	5.96
	Sensitivity to skin care/the skin care regimen	5.18	5.63	5.78
	Sensitivity to cold weather	4.41	5.53	6.08
	Redness	4.17	4.79	5.31
	Pimples or small red bumps	4.55	5	5.07
	Tingling, stinging or burning when cosmetic products are applied	5.24	5.83	6.19

Griffiths scale score key (scale from 0 to 4): 0 – none visible, 4 – severe condition.

Consumer survey score key (scale from 1 to 7): 1 – very poor condition, 7 – outstanding condition.

also confirmed clinically by the excellent product tolerance; erythema, scaling, and dryness were the same in the FFG and the PG and were improved in both groups over 12 weeks (Griffiths scale) as well as via responses of the study participants on questions relating to product tolerance in consumer survey (Table 3).

There was no significant change in the number of proliferating cells of either the PG or FFG, as determined by the number of positive cells in the biopsy samples stained for Ki67-protein (immunohistochemistry²³; Figure 4E).

In the subset of 15 patients at Site 3, dermal thickness was measured by high-resolution skin ultrasound using the Cortex system. The average dermal thickness in the FFG (11 subjects) was increased from 1.49 mm at baseline to 1.51 mm after 6 weeks and to 1.53 mm at 12 weeks (Figure 5A, Table 4). The PG (4 subjects) did not demonstrate an increased dermal thickness (average dermal thickness was 1.28 mm, 1.22 mm, and 1.26 mm at baseline, 6 weeks, and 12 weeks, respectively; Table 4). Although these numbers suggest a trend, statistical significance was not achieved.

Direct measurement of hematoxylin-eosin stained samples of the skin biopsies was performed at Sites 1 and 2. One FFG participant had a >80% increase in dermal thickness (from 1.25 mm at baseline to 2.28 mm after 12 weeks of treatment; Figure 5B). No PG participants demonstrated comparable data.

Clinical evaluation by Griffiths scale (42 subjects: 28 FFG and 14 PG group) revealed at least a one-grade improvement in visible pore size for the FFG vs PG at baseline compared to

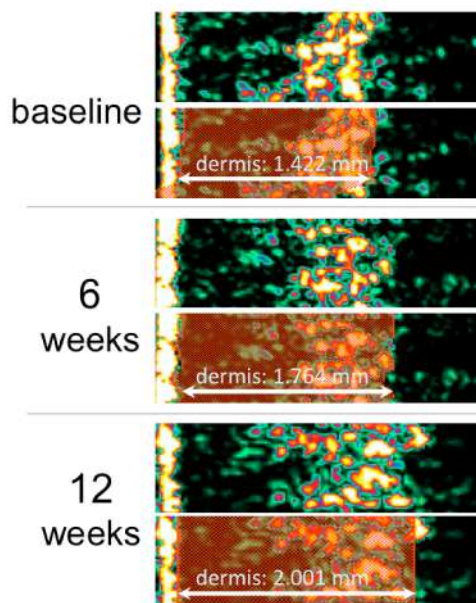
week 12 ($P=0.036$). This result was validated by the QuantifiCare analysis (12 subjects: 8 FFG and 4 PG) that demonstrated a significant improvement of the skin quality associated with visible pores at baseline compared to week 12 in the FFG vs the PG ($P=0.021$; Figure 6A). The 3-dimensional imaging confirms this observation (Figure 6B). It was notable that the treatment with the full formula caused not only the appearance of significant reduction in the number of visible pores, but also pore size and pore depth were reduced (Figure 6B).

While analyzing visible superficial wrinkles, we excluded all participants who had Griffiths Score 1 or 0 from the analysis. We surmised the moisturization provided by both the sunscreen and the cleanser may partially mask the effect from the tested treatment in mild aging. Therefore, in the analysis of superficial wrinkles using Griffiths scale we included only participants who scored 2, 3, or 4 at baseline (moderate and severe conditions). 21 participants of 25 of the FFG demonstrated at least 1 grade improvement in superficial wrinkles at week 6 or week 12 when evaluated in accordance with Griffiths scale, while in the PG only 6 participants of 12 showed any improvement. The result was statistically significant ($P=0.048$); the 3-dimensional- (Figure 7A, 7B) and micro- (Figure 7D) imaging confirm this observation. A clinical example of wrinkle reduction is shown in Figure 8.

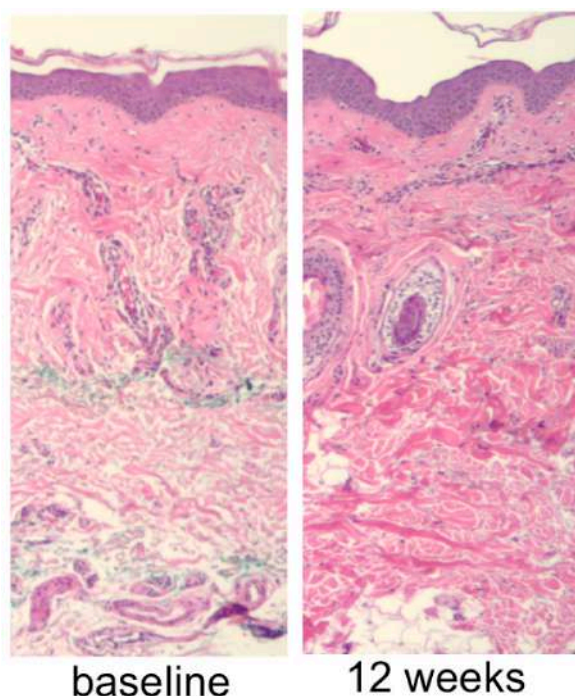
A combined analysis of parameters was also performed in the subgroup of patients who scored 3 or 4 at baseline (moderate- severe condition) in all: pores, superficial, and deep wrinkles. Nine participants from the FFG and three participants of the PG qualified for this inclusion criteria. While 7 of 9 participants (78%) from the FFG demonstrated improvement

FIGURE 5. Some participants of the Full Formula group demonstrated increase in dermal thickness. (A) High-resolution skin ultrasound demonstrates the increase in dermal thickness in the best participant (#18). Dermis area is highlighted in red. Original ultrasound image is shown above the red-highlighted image. Image was acquired using the High-Resolution Ultrasound Skin-Imaging System (DermaLab® SkinLab Combo, Cortex Technologies, Denmark). (B) Hematoxylin and Eosin staining of skin biopsy samples collected from participant #10 of the Full Formula group, showing increased dermal thickness. Photos were taken at 10x magnification.

(A)



(B)

**TABLE 4.**

Dermal Thickness Measured by High-Resolution Skin Ultrasound				
Group	Participant#	Thickness of dermis, mm		
		Baseline	6 weeks	12 weeks
Placebo	26	1.238	1.211	1.238
	28	1.264	1.132	1.264
	29	1.369	1.317	1.264
	30	1.264	1.238	1.264
	Average per group	1.283	1.224	1.257
Full Formula	16	1.501	1.317	1.106
	17	1.58	1.606	1.396
	18	1.422	1.764	2.001
	19	1.659	1.685	1.738
	20	1.554	1.606	1.606
	21	1.659	1.58	1.606
	22	1.475	1.554	1.791
	23	1.343	1.343	no data
	24	1.369	1.422	no data
	25	1.685	1.554	1.369
	51	1.159	1.211	1.185
	Average per group	1.491	1.512	1.533

in all three criteria at week 6 or week 12, no participants of 3 (0%) in the PG had such improvement (Table 5); the result was statistically significant ($P=0.045$).

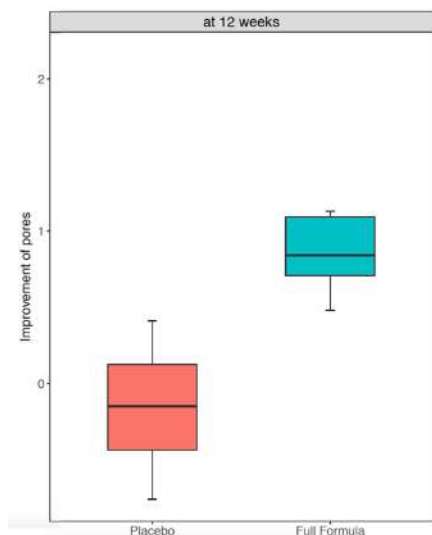
All 4 participants (100%) from the FFG who were randomly assigned to histopathological evaluation demonstrated an increase in the epidermal thickness and as well at least one grade improvement in ALL of the following: pores, hyperpigmentation, superficial, and deep wrinkles at week 6 or week 12 (Table 6). In contrast, zero participants of the PG (out of 3) who underwent histopathological evaluation, had improvement in all five parameters together (epidermal thickness, pores, hyperpigmentation, superficial, and deep wrinkles). This observation was also statistically significant ($P=0.029$).

Site 3 had means of evaluation utilizing 3D LifeViz (QuantifiCare, France) and DermaLab® SkinLab Combo suite (Cortex Technologies, Denmark).

The QuantifiCare analysis (12 subjects: 8 FFG and 4 PG) demonstrated a significant improvement in the score of “evenness” (Figure 9A; defined as the measurement of skin surface irregularity), as well as the score of “oiliness” (shiny parts of the skin, in association with pores, highlighting parts exhibiting sebum abnormalities; Figure 9B). These measurements were based on baseline values compared with week 12 in FFG vs PG: P values

FIGURE 6. Reduction of visible pores with the full formula. (A) Graphs represent position of tested persons (average per group) above population (QuantifiCare's reference data base: people of similar age, sex and skin type) in the parameter "Pores". The scores are provided on a scale between -2 and +2 representing the standard deviation relative to a matching population with respect to age, gender, and skin type (Fitzpatrick scale). +2 translates to excellent skin condition (undetected pores). -2 translates to poor skin condition (clearly visible pores). Pores were identified as the deepest pores in the region of interest (forehead) expressed as a percentage of all identified pores. Analysis was performed using QuantifiCare Clinical Imaging System (France). The mean differences between baseline and after treatment are shown. (B) 3-dimensional images of patient's skin (forehead; participant #51) demonstrating the reduction of visible pores. Images were acquired using 3D LifeViz II clinical imaging system (QuantifiCare, France). 3D-analysis and color indication have been performed using Skin Care module of LifeViz App (QuantifiCare, France): the deepest areas of pores are shown in blue, the low-profile pores are shown in red-yellow.

(A)



(B)

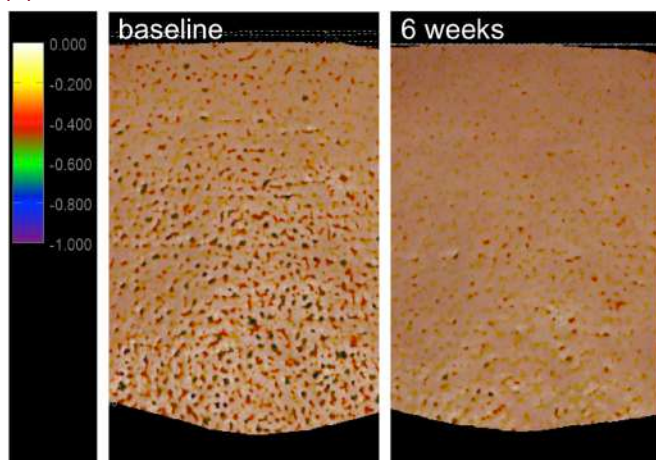
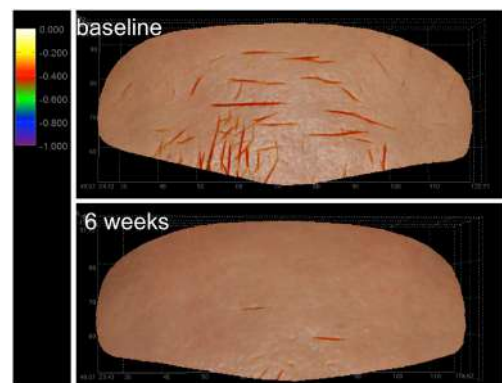
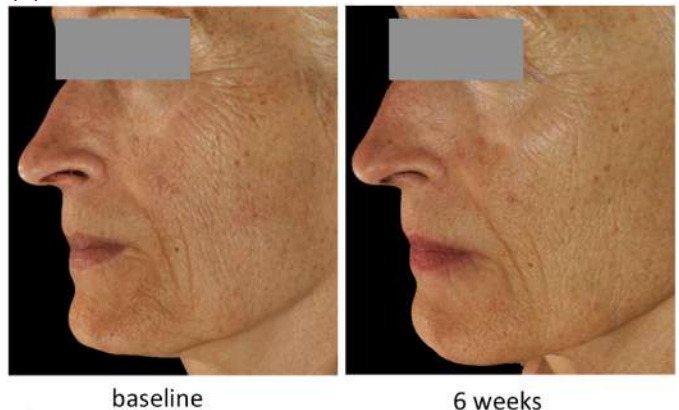

FIGURE 7. Reduction of visible wrinkles with the Full Formula. (A) 3-dimensional images of participant's skin (forehead). Images were acquired using QuantifiCare 3D LifeViz II clinical imaging system. 3D-analysis and color indication have been performed using QuantifiCare Skin Care module of LifeViz App: the deepest areas of wrinkles are shown in blue, the low-profile wrinkles are shown in red-yellow. Participant #51. (B) 3-dimensional reconstruction. Images were acquired using QuantifiCare 3D LifeViz II clinical imaging system. Participant #22. (C) Micro-imaging (QuantifiCare -MICRO clinical imaging system). Participant #16.

(A)



(B)



(C)

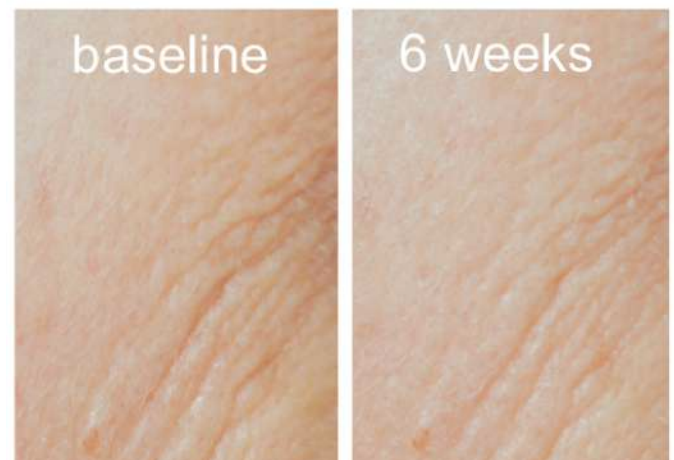
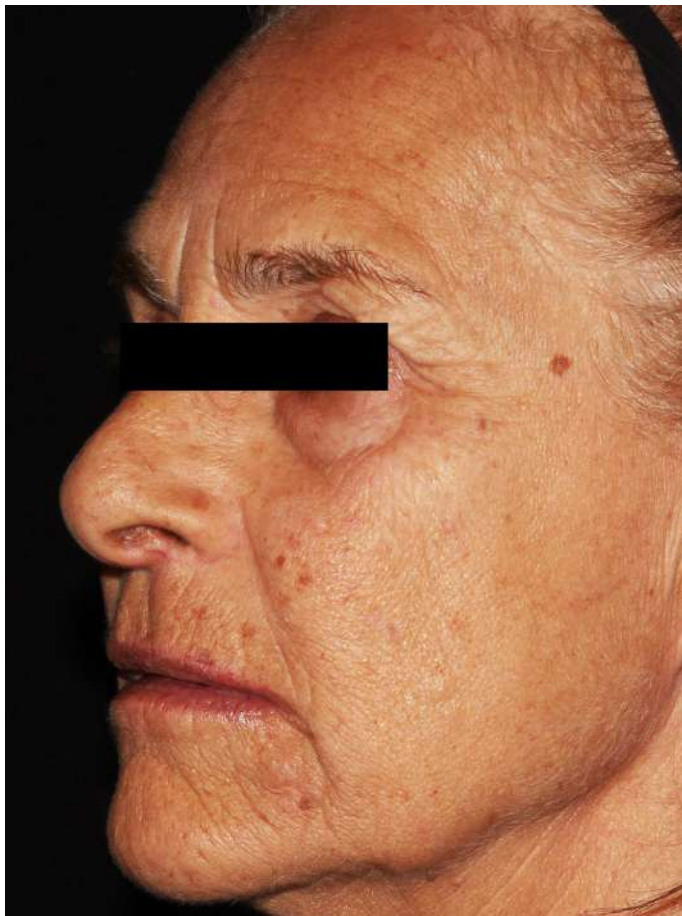
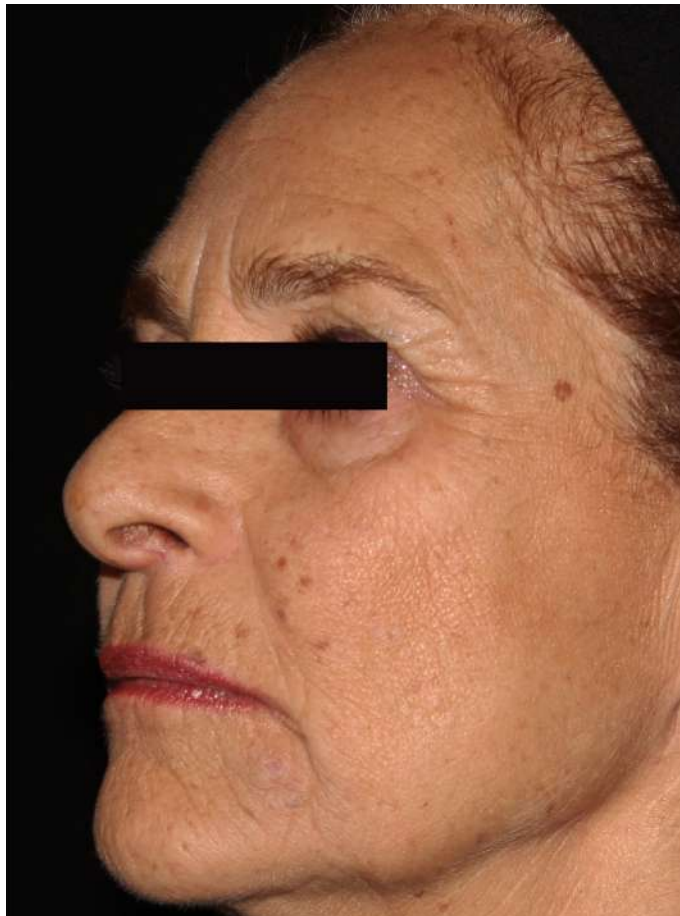FIGURE 8. Reduction of wrinkles with the Full Formula. High resolution photograph using Canfield CR of participant #10 in the FFG at baseline (A) and after 12 weeks (B).

(A)



(B)



were 0.023 for evenness and 0.008 for oiliness. Participants #22, #23, and #24 (all FFG) were excluded from the QuantifiCare analysis of skin's oiliness, evenness, and pore size due to the missing data on week 12 (no measurements).

Pigmentation was also significantly reduced, as measured by the SkinLab Combo Suite. Site 3 subjects (11 full formula

and 4 placebo) showed the average pigmentation index in the FFG was decreased from 42.09 to 40.35 after 6 weeks treatment (Figure 9C). The PG did not demonstrate improvement (pigmentation indexes were 41.45 and 41.52 at baseline and 6 weeks, respectively). This finding was statistically significant

TABLE 5.**Comprehensive Improvement of Participants With the "Worst" Skin Conditions**

Study Group	Number of Participants: subgroup of the "worst" skin conditions (score 3 or 4 at baseline)	Participants Who Improved in All: pores, superficial and deep wrinkles
Full Formula Group	9	7 (78%)
Placebo Group	3	0 (0%)

TABLE 6.**Epidermal Thickening Led to Improvement in All: pores, hyperpigmentation superficial and deep wrinkles**

Study Group	Number of Participants in Histology-Subgroup	Participants Who Improved in All: epidermal thickness, pores, hyperpigmentation, superficial, and deep wrinkles
Full Formula Group	4	4 (100%)
Placebo Group	3	0 (0%)

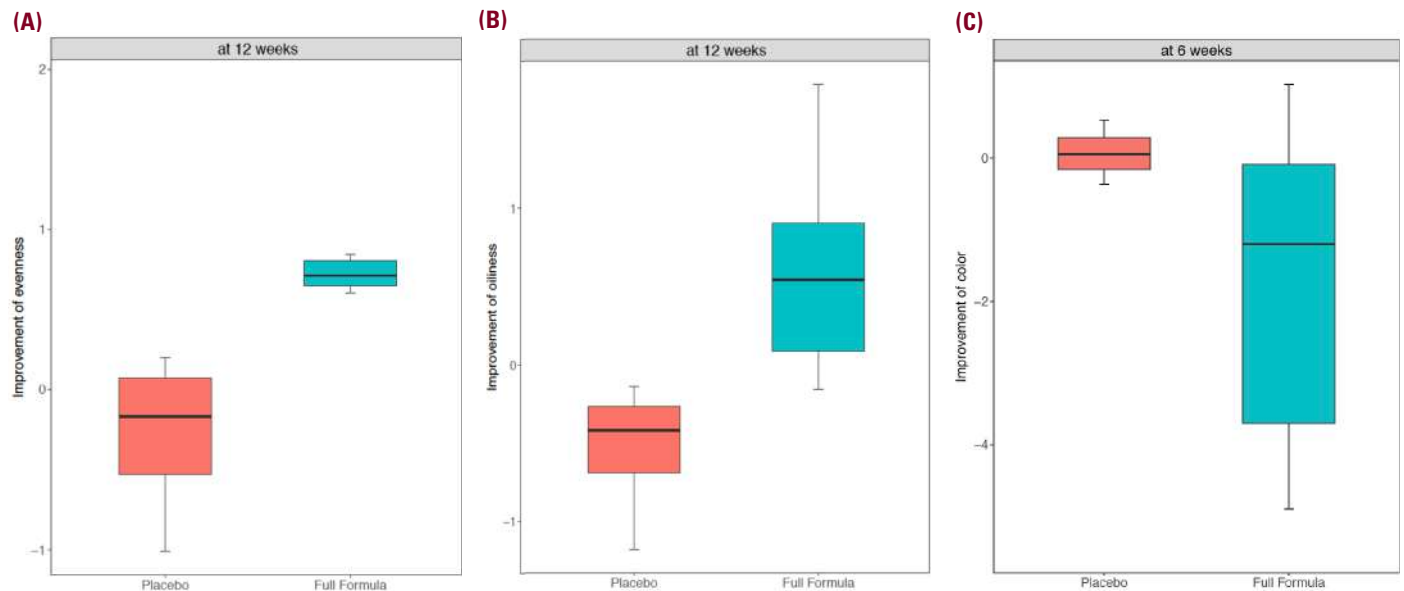
© 2018-Journal of Drugs in Dermatology. All Rights Reserved.

This document contains proprietary information, images and marks of Journal of Drugs in Dermatology (JDD).

No reproduction or use of any portion of the contents of these materials may be made without the express written consent of JDD.

If you feel you have obtained this copy illegally, please contact JDD immediately at support@jddonline.com

FIGURE 9. Improvement of skin's evenness, oiliness, and color with the full formula. (A, B) Graphs represent position of tested persons (average per group) above population (QuantifiCare's reference data base: people of similar age, sex, and skin type) in the parameters "Evenness" and "Oiliness" respectively. The scores are provided on a scale between -2 and +2 representing the standard deviation relative to a matching population with respect to age, gender, and skin type (Fitzpatrick scale). +2 translates to excellent skin condition. -2 translates to poor skin condition. Evenness was identified as a global measurement of skin surface irregularity in region of interest (forehead) depending on the fine or coarse texture of the skin. Oiliness was identified as shiny parts of the skin, in association with pores, highlighting parts exhibiting sebum abnormalities. Analysis was performed using QuantifiCare Clinical Imaging System (France). The mean differences between baseline and after treatment are shown. (C) Treatment with full formula led to brightening skin during 6 weeks of treatment. Skin color was measured using DermaLab® SkinLab Combo (Cortex Technologies, Denmark). The mean differences (pigmentation index) between baseline and after treatment are shown.



($P=0.016$). Clinically, reduction of melanin was noted in a variety of patients (Figures 10,11).

Transepidermal water loss (TEWL) and skin conducting properties (hydration) were measured by this system also. The average TEWL in the FFG (11 subjects) was decreased from 32.54 mg/cm²/hour at baseline to 11.24 mg/cm²/hour after 6 weeks and to 15.02 mg/cm²/hour at 12 weeks. The PG (4 subjects) did not demonstrate improvement in TEWL, the average TEWL were 19.03 mg/cm²/hour, 15.68 mg/cm²/hour, and 24.20 mg/cm²/hour at baseline, 6 weeks, and 12 weeks, respectively. However, the P value was >0.05 . The average skin electrical conductance in the FFG (8 subjects) was increased from 174.6 μ S at baseline to 224.3 μ S at week 12 (increasing skin conductivity reflects increased hydration). The average skin conductance in the PG (3 subjects) was 184.0 μ S and 185.1 μ S at baseline and 12 weeks, respectively. Although a trend was noted favorably in the FFG, no significance was established. Participants #23 and #24 (both FFG) were excluded from the analysis of TEWL and skin hydration at week 12 due to the missing data (no measurements). Participants #26 (PG) and #21 (FFG) were excluded from the analysis of skin hydration due to incorrect measurements either at baseline or week 12.

Skin elasticity in a subset of 8 patients (6 FFG, 2 PG) was measured using the SkinLab Combo. The average skin retraction

time in the FFG was decreased from 450 ms at baseline to 321 ms at week 12; the times in the PG were 589 ms and 598 ms at baseline and 12 weeks, respectively, demonstrating no improvement (Figure 12). However P value was >0.05 . Participants #16, #17, #23, and #24 (all FFG) were excluded from the analysis of skin elasticity due to the missing data at baseline (#16 and #17) or week 12 (#23 and #24; no measurements). Participants #29 (PG), #30 (PG), and #18 (FFG) were excluded from the analysis of elasticity due to incorrect measurements at week 12, electrical conductance (hydration) and retraction time (elasticity) are both very technically difficult methods.

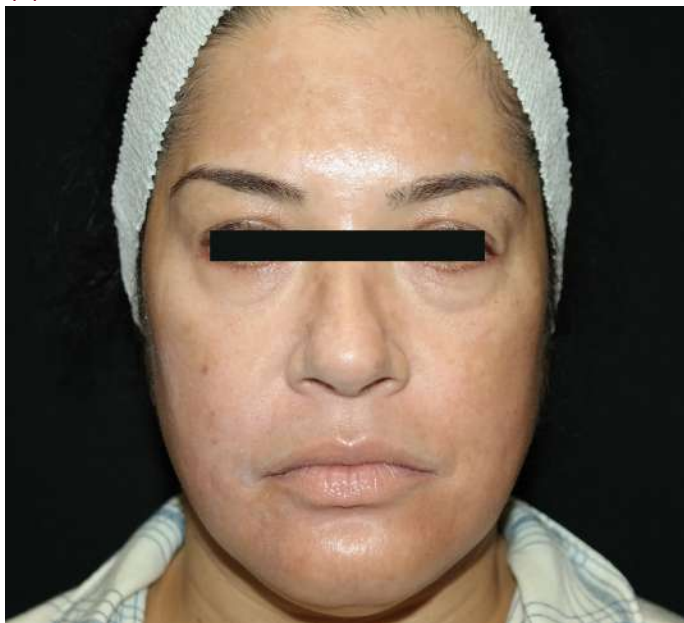Using a high-resolution skin ultrasound, a sub-epidermal low echogenicity band (SLEB) was analyzed. We observed that 4/9 in the FFG who underwent SLEB evaluation demonstrated improvement of signs of elastosis (Figure 13). For example, participant #20 demonstrated the reduction of SLEB from 0.974 mm to 0.895 mm at 6 weeks. Zero PG participants demonstrated comparable data.

DISCUSSION

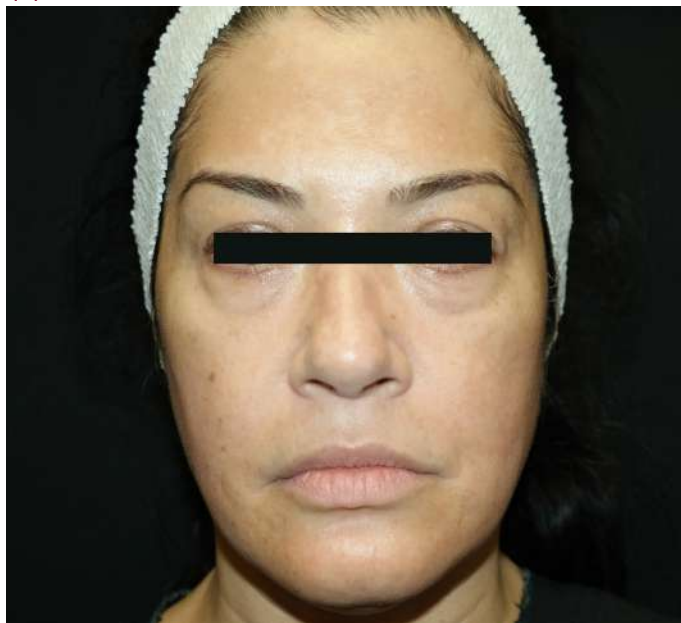The present study shows that the full formula skin care products containing the messaging peptides alpha- defensin 5 and beta defensin 3: (1) globally improve the visual appearance of aging skin, (2) do not stimulate proliferation of cells based

FIGURE 10. Improvement in melanin Participant #32 in FFG at baseline (A) and at 12 weeks (B).

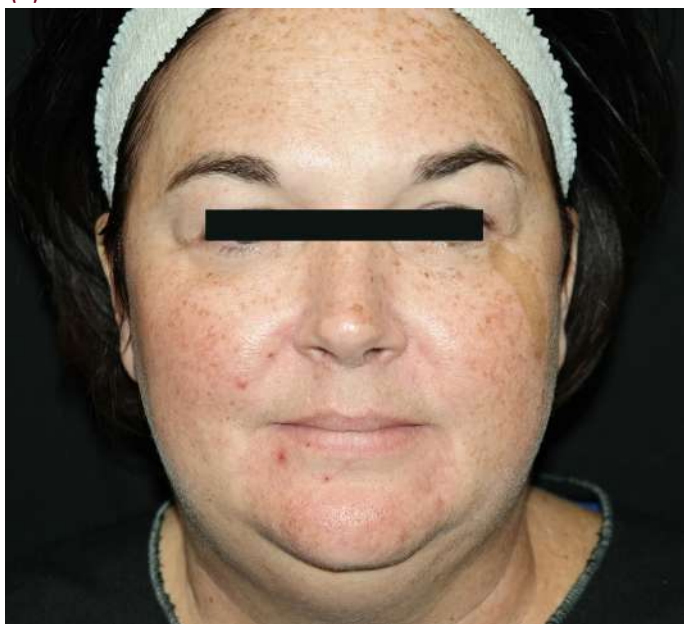(A)



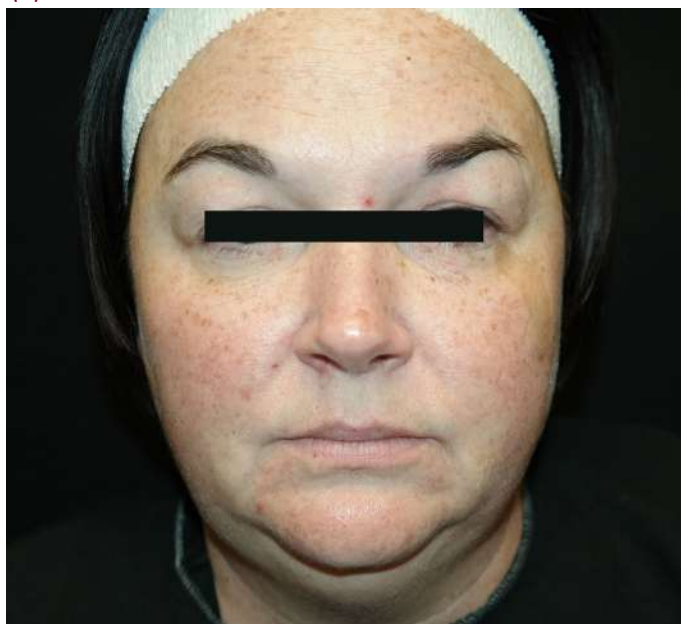(B)

**FIGURE 11.** Improvement of melanin in Participant #42 in FFG at baseline (A) and at 12 weeks (B).

(A)



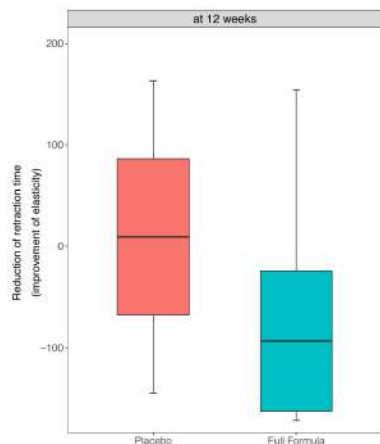
(B)



on no noted increase in the cancer-associated Ki67 marker, (3) improve specific multiple manifestations of aging skin, (4) thickens the epidermis without the irritation, dryness, or inflammation associated with retinols, and (5) is effective in a variety of skin types. These observations support the mechanism of action hypothesis that defensins activate the body's own skin stem cells to generate healthy new epidermal cells.

The defensins specifically stimulate young and "preserved" LGR6-positive stem cells.¹⁰ These skin's master stem cells ("master" because these give rise to the entire lineage of the epidermal cells)^{8,9} accumulate less mutations and damage than actively proliferating basal stem cells due to their quiescent status and "safe" residence in the isthmus, which is not as directly exposed to UV radiation as basal stem cells.²⁰ By activating

FIGURE 12. Improvement of skin's elasticity with the Full Formula. Skin elasticity was evaluated based on the measurement of skin's retraction time after suction applied to the skin surface. The measurement was performed using DermaLab® SkinLab Combo (Cortex Technologies, Denmark). The mean differences (retraction time) between baseline and after treatment are shown.

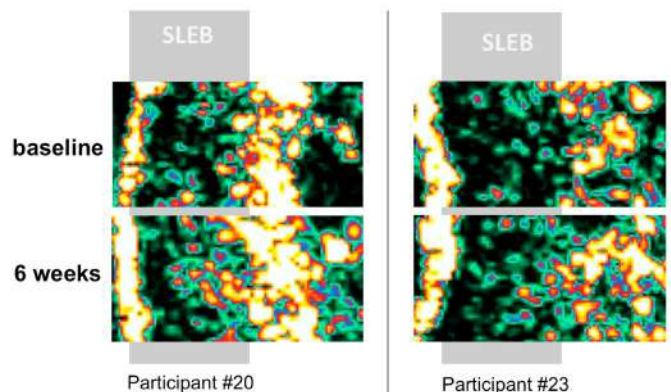


LGR6-positive stem cells, there would be differentiation and proliferation of less damaged keratinocytes. Thus, using a dormant resource of our own body, defensins may stimulate the LGR6-positive cells to create a relatively new and “fresh” epidermis.

In contrast, topical products that contain a variety of growth factors activate fibroblasts, keratinocytes, endothelial cells, macrophages, and other cellular elements¹⁹ that are not “young” cells; they have been present in the skin for an undetermined length of time and subject to mutation and other damaging elements during their lives. Stimulation of these “old” cells by growth factor cosmeceuticals would thus produce more cells potentially damaged by mutation, and/or cells with reduced function due to senescence unlike defensin-activated LGR6-positive stem cells, which produce these newer, non-mutated, and higher functioning skin cells.

Topical growth factors emerged as potential agents for skin rejuvenation^{18,24} about 15 years ago. Drawbacks are that they are unstable when not in their original environment, and that surfactants, oils, and other inactive substances in topical formulations can denature and inactivate them.²⁵ In contrast, defensin-peptides in the full formula are encapsulated in liposomes that prevent their contact with excipients and provide a physiologic microenvironment. With growth factors, penetration through the epidermis is limited by their high molecular weight (20-150 kDa) and hydrophilic nature.¹⁸ The target for stimulation (LGR6-positive stem cells) of the defensins (that have molecular weight of just 3-5 kDa) is located in the hair follicle which can be easily reached through the follicular orifice without the need to penetrate through stratum corneum. The

FIGURE 13. Some participants of the Full Formula group demonstrated improvement of signs of elastosis. The appearance of elastosis was evaluated based on the appearance of a subepidermic low echogenic band (SLEB). Image acquisition and measurements were performed using the High-Resolution Ultrasound Skin-Imaging System (DermaLab® SkinLab Combo, Cortex Technologies, Denmark).



liposome solution also contains a high concentration of recombinant albumin, which acts as a carrier protein²⁶ that protects the active molecules from degradation and is commonly used in cell therapies for stabilization of cytokines^{27,28}; albumin also helps to preserve proper structural conformation of the defensins,²⁶ thus ensuring their physiologic functionality.

Another concern with growth factors is that in stimulating aging cells, they may also stimulate carcinogenesis, especially if growth factors are up-regulated.¹⁸ This concern is supported by the presence of receptors for growth factors on melanoma cells and the expression of specific growth factors by malignant cells.²⁹ Although an FDA investigation showed that the potential for carcinogenesis requires concentrations of growth factors much higher than those found in topical products,¹⁸ the possibility still exists that older skin cells may have already mutated to cutaneous malignancy. Growth factors secreted by in vitro cultured human cells are widely used in cosmetic products.²⁵ A variety of sources of human cells is used including human fibroblasts, mesenchymal stem cells, and placental stem cells.²⁵ Over several decades of cancer research, hundreds of peer-review studies unlocked the mechanisms of carcinogenesis, gene expression pathways involved in tumor formation, and specific role of growth factors that may alter and/or stimulate cancer-associated gene-regulatory mechanisms.³⁰ This comprehensive knowledge brings a number of concerns relating to the use of undefined compositions of growth factors for skin care purposes. For example, transforming growth factor-beta (TGF- β), also known as a tumor growth factor, is present in most of the conditioned media.^{31,32} Multiple cancer research studies show that TGF- β is a potent trigger of the cancer-related pathways.^{33,34} TGF- β overproduction, as a driver of the fibrotic process of chronic phases of inflammatory diseases, precedes

tumor formation and prepares a favorable microenvironment for cancer cells.^{35,36}

Defensins, however, have not been linked with cancer and some tissues respond to tumor growth by enhanced expression of defensins as a natural protective immune response.³⁷ Studies also show the ability of defensins to suppress tumor growth both in vitro and in vivo.^{12, 38-40}

Immunochemical analyses of biopsy specimens in the present study failed to reveal an elevated number of epidermal cells expressing Ki-67, a DNA-binding nuclear protein expressed throughout the cell cycle in proliferating but not dormant cells.⁴¹ As a biomarker, Ki-67 has significant prognostic and/or predictive value in cancers such as cutaneous malignant melanoma,⁴² basal cell carcinoma,⁴³ breast,⁴⁴ prostate,⁴⁵ and colorectal.⁴⁶ Overexpression of Ki-67 is also associated with malignant melanoma,⁴⁷ and cancers of the brain,⁴⁸ kidney,⁴⁹ lung,^{41,50,51} ovary,⁵² and thyroid gland.⁵³ Although the findings of the present study do not prove the absence of an association of the full formula with skin cancer, it supports the contention that the full formula does not appear to stimulate carcinogenic properties of cells by 4 factors: 1) the tumor associated Ki-67 antigen was not increased in the study period, 2) defensins have been associated with natural tumor immunity, 3) defensins stimulate new cells that should be mutation-free, and 4) defensins are very specific in their target whereas growth factor mixes have multiple targets, making it more difficult to track their adverse effects.

The efficacy of topical retinoids, particularly tretinoin, for the treatment of photoaged skin is well established.⁵⁴⁻⁵⁹ Biopsies of patients treated daily with tretinoin cream (0.001-0.1%) for 3 to 6 months show compaction of the stratum corneum, increased number of granular layers, epidermal thickening, and a reduction in epidermal melanin.^{55,56} Characterized by erythema, peeling, pruritis, and burning at the treated sites, the “retinoid effect” is also well known.^{56, 60-62} This effect is thought to start by the release of proinflammatory cytokines such as IL-1, TNF- α , IL-6, and IL-8,^{63,64} a hypothesis supported by the work of Kim and colleagues⁶¹ who showed that retinol-induced inflammation was mediated by changes in the mRNA expression of pro-inflammatory cytokines. Retinoid therapy is also associated with photosensitization, which typically begins early in therapy.⁶⁰

The present study shows that treatment with the full formula significantly increases epidermal thickness as seen in the histopathological analysis, an observed result that is similar to those seen in topical treatments containing retinol,⁶⁵ but the full formula achieved this without accompanying inflammation.^{60,61,66} In addition, the full formula reduced pigmentation and also may have a benefit of increasing the skin's immunity against cancer. These are all things routinely touted as advantages of retinol and retinoids, yet they were accomplished by the full formula without

the adverse effects of peeling, erythema, and diminished compliance that are found with retinol.

The full formula products also specifically and significantly reduced visible pores, coarse and fine wrinkles, oiliness, evenness, and pigmentation. Improvements in pores and in both coarse and fine wrinkles were shown clinically by the Griffith scale data, and objectively by three-dimensional imaging. The observations also correlated with the significant improvement of skin's evenness—a global measurement of skin surface irregularity and roughness depending on the fine or coarse texture of the skin, that was measured using QuantifiCare system. In addition, the significant improvement in pores was confirmed by actual measurement of the pores using the QuantifiCare technology that evaluated pore size, number of pores, and pore depth. Reduction in pigmentation was shown and quantified by the Cortex system, and improvement on skin's oiliness was measured by QuantifiCare system.

Enlarged pores is a chronic and frequent complaint of patients, even in those without acne. It has never had a real histopathologic construct and we don't know the etiology for these in aging. However, reducing pore size is a unique finding for a skin care product that does not possess any exfoliating capacity. A conundrum of aging is the combination of enlarged pores and dryness, leading often to frustrated patients who are desirous of using retinol due to its anti-aging and pore-reducing properties, but cannot due to the concomitant irritation and xerosis experienced. The full formula product may be the first to offer the unique combination of thickened epidermis, reduced pore size, and reduced wrinkles without an increase in inflammation or irritation and without any reduction of stratum corneum, with its attendant increase in sun sensitivity.

In fact, in analyzing the data further we have found that 78% of the participants who had severe conditions in all 3 parameters (enlarged pore size, superficial, and deep wrinkles) at baseline, had significant improvement in all three parameters after treatment. Zero participants (0%) in the PG have demonstrated this finding. Moreover, participants of the FFG in the subset of patients who had biopsies who improved in epidermal thickness also improved in all: pores, superficial and deep wrinkles, and hyperpigmentation, whereas zero participants in the PG demonstrated similar improvement. This observation is consistent with the proposed mechanism of action being the activation of LGR6-positive stem cells, leading to creation of a “new epidermis” (new and young epidermis cells). This should result in the normalization of the entire epidermis and ultimately to global improvement of the skin—exactly what was observed when improvement was analyzed as a complex of skin parameters.

These results show that the defensin-containing trio of products offer most of the advantages of time-honored retinols as well as newer but widely used growth-factor containing

cosmeceuticals, without irritation or inflammation, sun-sensitivity, or concerns about neoplasia of the treated skin.

CONCLUSION

An alpha-defensin 5 and beta-defensin 3 containing skin care regimen of 3 products (1) globally and statistically significantly improves the visual appearance, coarse and fine wrinkles, appearance of pores, uneven texture, and thickness of the epidermis of aging skin without the irritation and dryness or increased sun-sensitivity associated with the use of retinols, and (2) stimulates skin rejuvenation without apparent carcinogenic risk. The data is consistent with the proposed mechanism of action that defensins activates the body's own dormant stem cells to generate healthy new epidermal cells. Collectively, these findings may represent a paradigm shift in cosmeceutical skin care.

DISCLOSURES

Dr. Taub is part owner of MediCell Technologies LLC and serves on its Medical Advisory Board. She has also performed research, received honoraria (from), and given speaking presentations for MediCell.

Dr. Bucay is part owner of MediCell Technologies LLC and serves on its Medical Advisory Board. She has also performed research and given speaking presentations for MediCell.

Dr. Keller is part owner of MediCell Technologies LLC, Chief Medical Officer and Chairman. He has also performed research and given speaking presentations for MediCell.

Dr. Jay Williams and Dr. Mehregan have no conflicts.

REFERENCES

- Ojeh N, Pastar I, Tomic-Canic M, et al. Stem cells in skin regeneration, wound healing, and their clinical applications. *Int J Mol Sci*. 2015;16(10):25476-25501.
- Blanpain C, Fuchs E. Epidermal stem cells of the skin. *Annu Rev Cell Dev Biol*. 2006;22:339-373.
- Braun KM, Prowse DM. Distinct epidermal stem cell compartments are maintained by independent niche microenvironments. *Stem Cell Rev*. 2006;2(3):221-231.
- Bardelli S, Moccetti M. Remodeling the human adult stem cell niche for regenerative medicine applications. *Stem Cells Int*. 2017;2017:6406025.
- Taub AF. Molecular biology of adipose-derived adult stem cells. In: Katz BE, Sadick NS, eds. *Procedures in Cosmetic Dermatology Series: Body Contouring*. Cambridge, MA: Saunders Elsevier Inc.; 2010:31-42.
- Plikus MV, Gay DL, Treffeisen E, et al. Epithelial stem cells and implications for wound repair. *Semin Cell Dev Biol*. 2012;23:946-953.
- Ito M, Liu Y, Yang Z, et al. Stem cells in the hair follicle bulge contribute to wound repair but not to homeostasis of the epidermis. *Nat Med*. 2005;11(12):1351-1354.
- Snippert HJ, Haeghebarth A, Kasper M, et al. Lgr6 marks stem cells in the hair follicle that generate all cell lineages of the skin. *Science*. 2010;327:1385-1389.
- Lough DM, Yang M, Blum A, et al. Transplantation of the LGR6+ epithelial stem cell into full-thickness cutaneous wounds results in enhanced healing, nascent hair follicle development, and augmentation of angiogenic analytes. *Plast Reconstr Surg*. 2014;133(3):579-590.
- Lough D, Dai H, Yang M, et al. Stimulation of the follicular bulge LGR5+ and LGR6-positive stem cells with the gut-derived human alpha defensin 5 results in decreased bacterial presence, enhanced wound healing, and hair growth from tissues devoid of adnexal structures. *Plast Reconstr Surg*. 2013;132(5):1159-1171.
- Schneider JJ, Unholzer A, Schaller M, et al. Human defensins. *J Mol Med (Berl)*. 2005;83(8):587-595.
- Hanaoka Y, Yamaguchi Y, Yamamoto H, et al. In vitro and in vivo anticancer activity of human β -defensin-3 and its mouse homolog. *Anticancer Res*. 2016;36(11):5999-6004.
- Lichtenstein A, Ganz T, Selsted ME, et al. In vitro tumor cell cytotoxicity mediated by peptide defensins of human and rabbit granulocytes. *Blood*. 1986;68(6):1407-1410.
- Biragyn A, Ruffini PA, Leifer CA, et al. Toll-like receptor 4-dependent activation of dendritic cells by β -defensin 2. *Science*. 2002;298(5595):1025-1029.
- Han W, Wang W, Mohammed KA, et al. Alpha-defensins increase lung fibroblast proliferation and collagen synthesis via the beta-catenin signaling pathway. *FEBS J*. 2009;276(22):6603-6614.
- Semple F, Dorin JR. β -Defensins: multifunctional modulators of infection, inflammation and more? *J Innate Immun*. 2012;4(4):337-348.
- Kiatsurayanon C, Niyonsaba F, Smithrithee R, et al. Host defense (Antimicrobial) peptide, human β -defensin-3, improves the function of the epithelial tight-junction barrier in human keratinocytes. *J Invest Dermatol*. 2014;134(8):2163-2173.
- Sundaram H, Mehta RC, Norine JA, et al. Topically applied physiologically balanced growth factors: a new paradigm of skin rejuvenation. *J Drugs Dermatol*. 2009;8(5) (Suppl):4-13.
- Malerich S, Berson D. Next generation cosmeceuticals: the latest in peptides, growth factors, cytokines, and stem cells. *Dermatol Clin*. 2014;32(1):13-21.
- Campisi J, d'Adda di Fagnana F. Cellular senescence: when bad things happen to good cells. *Nat Rev Mol Cell Biol*. 2007;8(9):729-724.
- Federal Register (62 FR 25692). May 9, 1997.
- Griffiths CE, Wang TS, Hamilton TA, et al. A photometric scale for the assessment of cutaneous photodamage. *Arch Dermatol*. 1992;128(3):347-351.
- Gerdes J, Schwab U, Lemke H, et al. Production of a mouse monoclonal antibody reactive with a human nuclear antigen associated with cell proliferation. *Int J Cancer*. 1983;31:13-20.
- Gold MH, Goldman MP, Biron J. Efficacy of novel skin cream containing mixture of human growth factors and cytokines for skin rejuvenation. *J Drugs Dermatol*. 2007;6(2):197-201.
- Fabi S, Sundaram H. The potential of topical and injectable growth factors and cytokines for skin rejuvenation. *Facial Plast Surg*. 2014;30(2):157-571.
- Horvath DB, Simon M, Schwarz CM, et al. Serum albumin as a local therapeutic agent in cell therapy and tissue engineering. *Biofactories*. 2017;43(3):315-330.
- Ausubel LJ, Lopez PM, Couture LA. GMP scale-up and banking of pluripotent stem cells for cellular therapy applications. *Methods Mol Biol*. 2011;767:147-159.
- Turovets N, Fair J, West R, et al. Derivation of high-purity definitive endoderm from human parthenogenetic stem cells using an in vitro analog of the primitive streak. *Cell Transplant*. 2012;21(1):217-234.
- Liu B, Earl HM, Baban D, et al. Melanoma cell lines express VEGF receptor KDR and respond to exogenously added VEGF. *Biochem Biophys Res Commun*. 1995;217(3):721-727.
- Jaffee EM, Dang CV, Agus DB, et al. Future cancer research priorities in the USA: a Lancet Oncology Commission. *Lancet Oncol*. 2017;18(11):e653-e706.
- Meirelles Lda S, Fontes AM, Covas DT et al. Mechanisms involved in the therapeutic properties of mesenchymal stem cells. *Cytokine Growth Factor Rev*. 2009;20(5-6):419-427.
- Falanga V, Su Wen Qian V, Danielpour D, et al. Hypoxia upregulates the synthesis of TGF- β by human dermal fibroblasts. *J Invest Dermatol*. 1991;97(4):634-637.
- de Gramont A, Faivre S, Raymond E. Novel TGF- β inhibitors ready for prime time in onco-immunology. *Oncotarget*. 2016;6(1):e1257453.
- Neuzillet C, Tijeras-Raballand A, Cohen R, et al. Targeting the TGF β pathway for cancer therapy. *Pharmacol Ther*. 2015;147:22-31.
- Lopez-Novoa JM, Nieto MA. Inflammation and EMT: an alliance towards organ fibrosis and cancer progression. *EMBO Mol Med*. 2009;1:303-314.
- Jakowlew SB. Transforming growth factor-beta in cancer and metastasis. *Cancer Metastasis Rev*. 2006;25:435-457.
- Semple F, Dorin JR. β -Defensins: multifunctional modulators of infection, inflammation and more? *J Innate Immun*. 2012;4(4):337-348.
- Lichtenstein A, Ganz T, Selsted ME, et al. In vitro tumor cell cytotoxicity mediated by peptide defensins of human and rabbit granulocytes. *Blood*. 1986;68:1407-1410.
- Biragyn A, Ruffini PA, Leifer CA, et al. Toll-like receptor 4-dependent activation of dendritic cells by β -defensin 2. *Science*. 2002;298:1025-1029.
- Biragyn A, Surenhu M, Yang D, et al. Mediators of innate immunity that target immature, but not mature, dendritic cells induce antitumor immunity when genetically fused with nonimmunogenic tumor antigens. *J Immunol*. 2001;167:6644-6653.

© 2018 Journal of Drugs in Dermatology. All Rights Reserved.

This document contains proprietary information, images and marks of Journal of Drugs in Dermatology (JDD).

No reproduction or use of any portion of the contents of these materials may be made without the express written consent of JDD.

If you feel you have obtained this copy illegally, please contact JDD immediately at support@jddonline.com

41. Warth A, Cortis J, Soltermann A, et al. Tumour cell proliferation (Ki-67) in non-small cell lung cancer: a critical reappraisal of its prognostic role. *Br J Cancer*. 2014;111(6):1222-1229.
42. Henrique R, Azevedo R, Bento MJ, et al. Prognostic value of Ki-67 expression in localized cutaneous malignant melanoma. *J Am Acad Dermatol*. 2000;43(6):991-1000.
43. Barrett TL, Smith KJ, Hodge JJ, et al. Immunohistochemical nuclear staining for p53, PCNA, and Ki-67 in different histologic variants of basal cell carcinoma. *J Am Acad Dermatol*. 1997;37(3 Pt 1):430-437.
44. Cuzick J, Dowsett M, Pineda S, et al. Prognostic value of a combined estrogen receptor, progesterone receptor, Ki-67, and human epidermal growth factor receptor 2 immunohistochemical score and comparison with the Genomic Health recurrence score in early breast cancer. *J Clin Oncol*. 2011;29(32):4273-4278.
45. Khor LY, Bae K, Paulus R, et al. MDM2 and Ki-67 predict for distant metastasis and mortality in men treated with radiotherapy and androgen deprivation for prostate cancer: RTOG 92-02. *J Clin Oncol*. 2009;27(19):3177-3184.
46. Allegra CJ, Paik S, Colangelo LH, et al. Prognostic value of thymidylate synthase, Ki-67, and p53 in patients with Dukes' B and C colon cancer: a National Cancer Institute-National Surgical Adjuvant Breast and Bowel Project collaborative study. *J Clin Oncol*. 2003;21(2):241-250.
47. Henrique R, Azevedo R, Bento MJ, et al. Prognostic value of Ki-67 expression in localized cutaneous malignant melanoma. *J Am Acad Dermatol*. 2000;43(6):991-1000.
48. Johannessen AL, Torp SH. The clinical value of Ki-67/MIB-1 labeling index in human astrocytomas. *Pathol Oncol Res*. 2006;12:143-147.
49. Xie Y, Chen L, Ma X, et al. Prognostic and clinicopathological role of high Ki-67 expression in patients with renal cell carcinoma: a systematic review and meta-analysis. *Sci Rep*. 2017;7:44281.
50. Shiba M, Kohno H, Kakizawa K, et al. Ki-67 immunostaining and other prognostic factors including tobacco smoking in patients with resected nonsmall cell lung carcinoma. *Cancer*. 2000;89:1457-1465.
51. Chirieac LR. Ki-67 expression in pulmonary tumors. *Transl Lung Cancer Res*. 2016;5:547-551.
52. Battista MJ, Mantai N, Sicking I, et al. Ki-67 as an independent prognostic factor in an unselected cohort of patients with ovarian cancer: results of an explorative, retrospective study. *Oncol Rep*. 2014;31:2213-2219.
53. Dwivedi SS, Khandeparkar SG, Joshi AR, et al. Study of immunohistochemical markers (CK-19, CD-56, Ki-67, p53) in differentiating benign and malignant solitary thyroid nodules with special reference to papillary thyroid carcinomas. *J Clin Diagn Res*. 2016;10:EC14-EC19.
54. Kligman AM, Grove GL, Hirose R, et al. Topical tretinoin for photoaged skin. *J Am Acad Dermatol*. 1986;15(4 Pt 2):836-859.
55. Gilchrist BA. Retinoids and photodamage. *Br J Dermatol*. 1992;127 Suppl 41:14-20.
56. Weinstein GD, Nigra TP, Pochi PE, et al. Topical tretinoin for treatment of photodamaged skin. A multicenter study. *Arch Dermatol*. 1991;127(5):659-665.
57. Bhawan J. Short- and long-term histologic effects of topical tretinoin on photodamaged skin. *Int J Dermatol*. 1998;37(4):286-292.
58. Singh M, Griffiths CE. The use of retinoids in the treatment of photoaging. *Dermatol Ther*. 2006;19(5):297-305.
59. Hubbard BA, Unger JG, Rohrich RJ. Reversal of skin aging with topical retinoids. *Plast Reconstr Surg*. 2014;133(4):481e-490e.
60. Mukherjee S, Date A, Patravale V, et al. Retinoids in the treatment of skin aging: an overview of clinical efficacy and safety. *Clin Interv Aging*. 2006;1(4):327-348.
61. Kim BH, Lee YS, Kang KS. The mechanism of retinol-induced irritation and its application to anti-irritant development. *Toxicol Lett*. 2003;146(1):65-73.
62. Ascenso A, Ribeiro H, Marques HC, et al. Is tretinoin still a key agent for photoaging management? *Mini Rev Med Chem*. 2014;14(8):629-641.
63. Torras H. Retinoids in aging. *Clin Dermatol*. 1996;14(2):207-215.
64. Orfanos CE, Zouboulis CC, Almond-Roesler B, et al. Current use and future potential role of retinoids in dermatology. *Drugs*. 1997 Mar;53(3):358-388.
65. Duell EA, Derguini F, Kang S, et al. Extraction of human epidermis treated with retinol yields retro-retinoids in addition to free retinol and retinyl esters. *J Invest Dermatol*. 1996;107(2):178-182.
66. Griffiths CE, Finkel LJ, Tranfaglia MG, et al. An in vivo experimental model for effects of topical retinoic acid in human skin. *Br J Dermatol*. 1993;129(4):389-394.

AUTHOR CORRESPONDENCE

Amy Taub MD

E-mail:..... drtaub@advdermatology.com